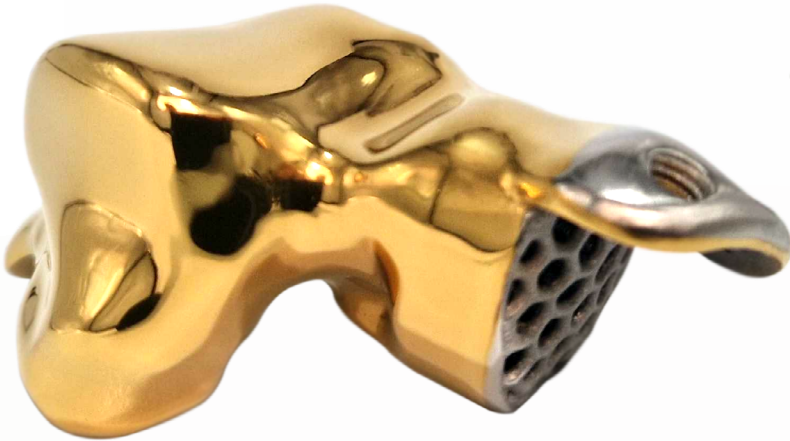



The role of 3D additive manufacturing in the treatment of Avascular Necrosis of the Talus. A comprehensive clinical guide.

Authors:
Mr. Mark B Davies,
Consultant Orthopaedic Surgeon (Foot & Ankle), BM, FRCS, FRCS (Tr&Orth)

Mr. Jitendra Mangwani,
Orthopaedic Surgeon (Foot & Ankle) MBBS (Gold medal), MS (Orth), MRCS (Ed), FRCS (Tr&Orth)

CONTENTS

01 ____

Introduction

01 ____

Presentation of talar AVN

02 ____

Clinical signs and symptoms for diagnosis

- Clinical assessment
- Radiographic signs of avascular necrosis of the talus

03 ____

Staging of the disease

03 ____

Solution algorithm for avascular necrosis of the talus

04 _____

Considerations of 3-D printed, additive manufacturing implants as a solution for talar AVN

- Indications
- Relative indications/contra-indications
- Patient selection - general considerations
- Consent
- Design and planning
- Surgical Approaches
- Imaging
- Operative planning in general
 - Microbiology
 - Surgical assistance & theatre support
 - Useful specific kit adjuncts

06 _____

Case example 1

08 _____

Case example 2

11 _____

Case example 3

14 _____

Case example 4

17 _____

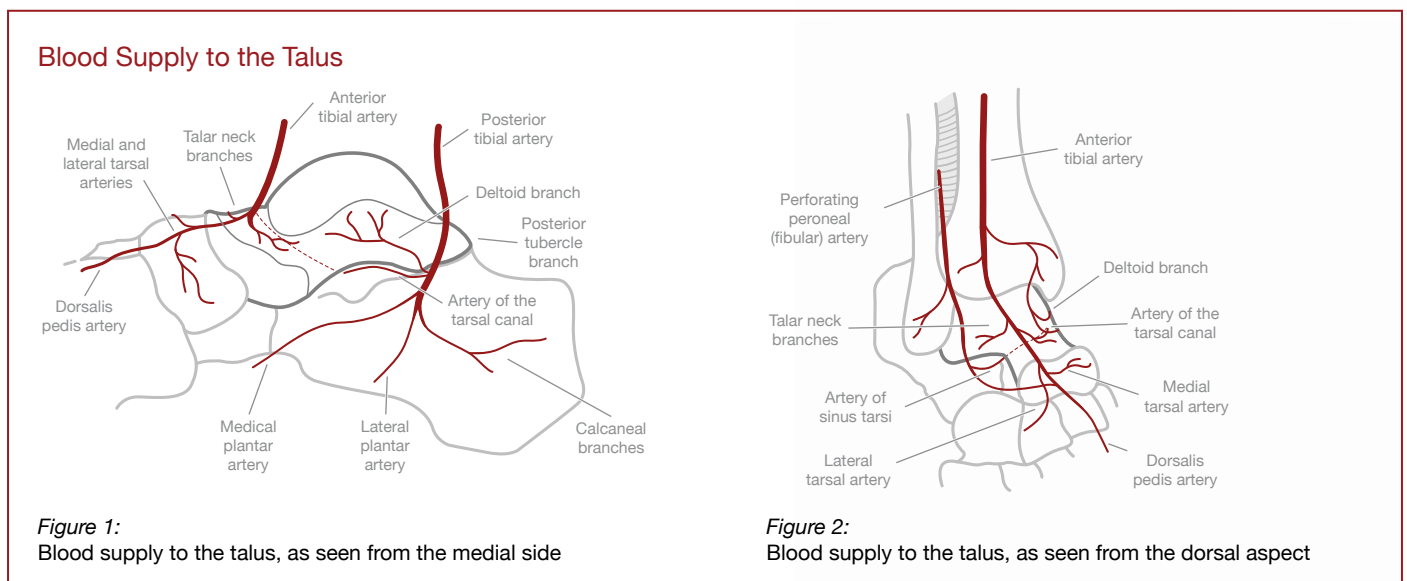
Reference list

INTRODUCTION

Avascular necrosis (AVN) or osteonecrosis of the talus results from temporary or permanent loss of blood supply to the bone leading to death of the talus (1). The aetiologies for avascular necrosis of the talus subdivide into atraumatic and traumatic causes (2,5). Up to 25% of cases are atraumatic in origin, including idiopathic reasons, prescribed or abuse of corticosteroid medication, alcoholism, hyperlipidaemia, irradiation, and thrombophilia (2). However, 75% cases are related to talar trauma, usually involving the body or neck of the talus.

Sixty percent of the talus is covered by hyaline cartilage permitting articulation with the tibial plafond, lateral malleolus, navicular and calcaneus. As a result, blood can only be supplied to the bone through ligamentous attachments on the remaining 40% of the bone. No muscles originate or insert onto the talus adding to the paucity of blood supply. Thus, the bone is inherently susceptible to AVN. The arterial supply of the talus is made up of both extraosseous and intraosseous circulation. Extraosseous supply stems from three sources: namely the posterior tibial artery (PTA), the dorsalis pedis artery, and the perforating peroneal artery contributing 47%, 36% and 17% respectively (3). In turn, these form a series of anastomoses with a key location for these anastomoses lying within the sinus tarsi. In a seminal MRA study by Miller et al, it was concluded that there is a wide range of contribution of each vessel to each of the anatomic regions of the talus. The wide ranges in the study's results may reflect the sample sizing or true anatomic variability. In a second statement from this paper, surgeons were urged caution in performing dual surgical incisions for talar fractures. In a second MRA study, Prasarn et al (4) also discovered a direct branch of the PTA supplying the medial neck of the talus in 75% of individuals and also a previously, undocumented branch of the PTA was found superior to the neck of the talus in 20% of individuals cautioning an anterior approach to the talus for fracture surgery. In 1970, the intraosseous blood supply to the talus was well documented through the classic study of sectioned cadaveric tali by Mulfinger and Trueta.

Owing to the inconsistent nature of the extra and intraosseous blood supply and the variable nature of the pathology behind AVN, the patterns of pathoanatomy of AVN vary. Broadly speaking, they can be grouped into partial and global AVN, with the former, usually principally affecting the body of the talus.



PRESENTATION OF TALAR AVN

Early stages of AVN may not present with many symptoms (5) and on occasions will be diagnosed as an incidental finding. Therefore, many patients, are not diagnosed until later stages of disease progression and often when talar collapse has subsequently occurred. The principle symptoms of AVN remains pain. Frequently, this pain mimics arthritic pain in being aggravated by bearing weight. However, a useful clue to AVN pain is the unremitting pain throughout the night and disturbance of sleep. Deformity may also be a presenting complaint of this condition.

The overarching goal of treatment is to provide pain relief for patients but also to halt progression of the disease and delay or prevent end-stage arthritis. Joint-preserving procedures are often attempted for pre-collapse stages; however, after severe subchondral collapse has occurred, hindfoot arthrodesis has been the mainstay of surgeries to relieve symptoms.

CLINICAL SIGNS AND SYMPTOMS FOR DIAGNOSIS

Clinical assessment

Thorough subjective history - Pain
Open or closed trauma to the talus
Previous surgery to the talus and outcome - infection, success
Significant past medical history
e.g. steroid use, excess alcohol consumption

Examine standing and walking for presence of any deformity and fixity of any deformity present (varus and equinus deformities being most common)

Ascertain initial injury pattern and surgical methods from available radiology and documentation

Explore potential vascular assessment

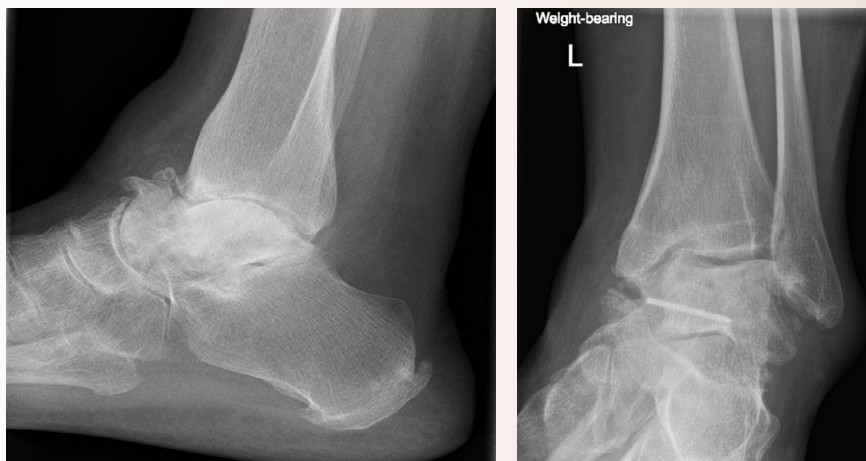Radiological signs of avascular necrosis of the talus

Plain radiographic assessment is the first technique used in imaging the foot and ankle to aid with the diagnosis of AVN (Figure 3). Other useful imaging includes both CT and MRI (Figures 4 & 5). All three techniques can determine arthrosis, sclerosis, collapse, mal-union and non-union.

X-RAY

- Sclerosis
- Malunion
- Non-union
- Collapse
- Arthrosis

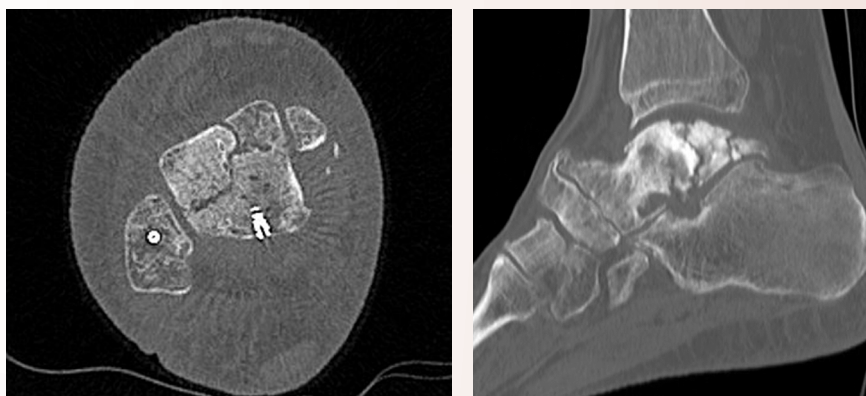
Figure 3:
Plain x-ray lateral and AP views,
demonstrating radiographic signs of talar AVN



CT

- Fracture lines
- Non-union
- AVN
- Collapse
- Arthrosis

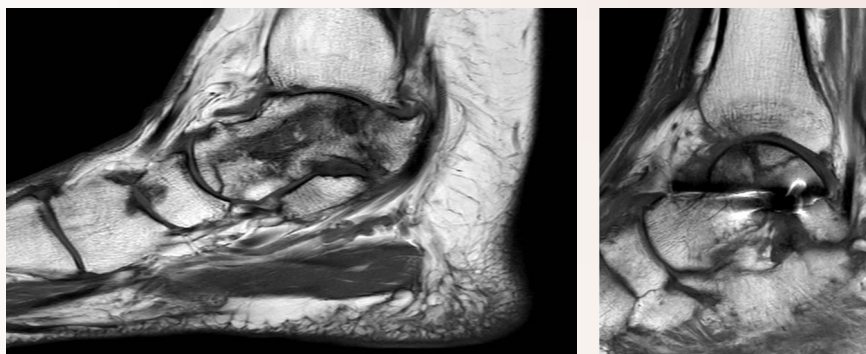
Figure 4:
CT axial and sagittal slices, demonstrating
radiographic signs of talar AVN



MRI

- May be less helpful especially with retained hardware in-situ
- Serpiginous lines on T1 sequences (snaky shaped lines through the bone)

Figure 5:
MRI sagittal slices, demonstrating
radiographic signs of talar AVN



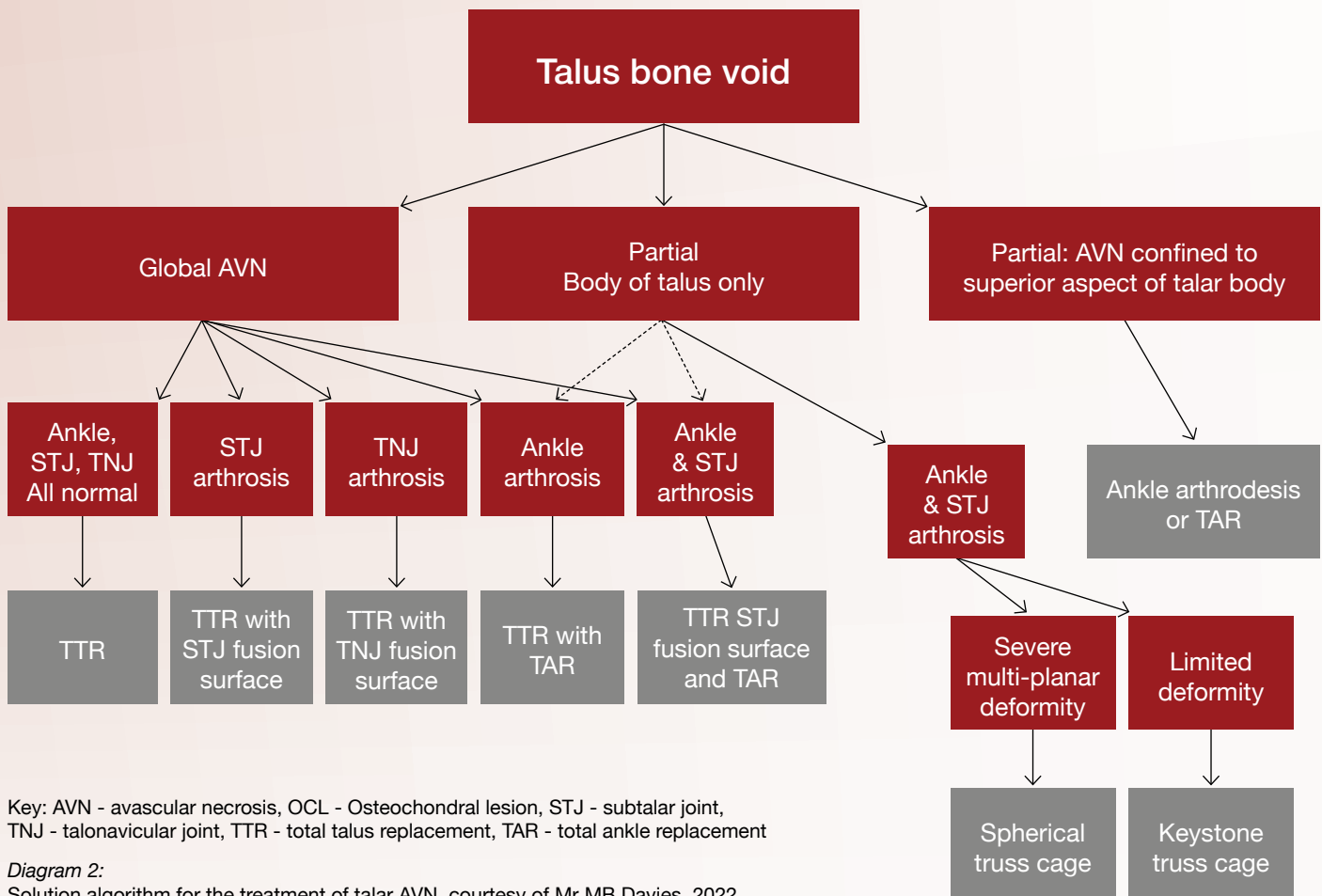
STAGING OF THE DISEASE

Unfortunately, no specific staging system has been developed for talar AVN. The classic Ficat and Arlet staging system was designed for AVN of the femoral head and has been extrapolated for use in the talus (Diagram 1). Nonetheless, it remains the sole logical tool to try and guide treatment.

Ficat and Arlet Staging of Osteonecrosis	
Stage	Radiographic finding
I	Normal
II	Cystic &/or sclerotic lesions, normal talar contour, no subchondral fractures
III	Crescent sign, subchondral collapse
IV	Joint-space narrowing, secondary tibial cysts, osteophytes, arthritic changes

Diagram 1:
Ficat and Arlet Staging of Osteonecrosis

SOLUTION ALGORITHM FOR AVASCULAR NECROSIS OF THE TALUS



Key: AVN - avascular necrosis, OCL - Osteochondral lesion, STJ - subtalar joint, TNJ - talonavicular joint, TTR - total talus replacement, TAR - total ankle replacement

Diagram 2:
Solution algorithm for the treatment of talar AVN, courtesy of Mr MB Davies, 2022

CONSIDERATIONS OF 3-D PRINTED, ADDITIVE MANUFACTURING IMPLANTS AS A SOLUTION FOR TALAR AVN.

The additive manufacturing process has opened up avenues for dealing with difficult cases where a void requires filling in the foot or ankle. Such voids can be seen in partial or global AVN of the talus. Conventional surgical techniques relied upon simple resection of diseased bone with the void filled by fusing the calcaneus to the tibial plafond. One such technique was described by Blair. Unfortunately, this leads to significant loss of length of the lower limb and can be poorly tolerated by the patient and can lead to long-term attendant ramifications. Circular fine wire frames and distraction osteogenesis can restore length in some cases but is technically challenging for the surgeon and has a significant impact on the patient during a lengthy treatment.

Other techniques in late stage AVN include resecting the dead parts of the talus and, employing either or bulk allograft to fill the void and a tibio-talo-calcaneal fusion is performed. Although this can be successful, there is a well appreciated risk of this graft not being incorporated in up to 33-50% of patients. This can result in painful non-union. As with all surgical technical tips, the key to success are the tips that start with careful planning.

Indications

There are more niche indications than those listed below, but in decreasing order of incidence, these pathologies have been successfully treated using 3-D printed trusses.

- Established avascular necrosis (AVN) of the talus
- Failed total ankle replacement (TAR)
- Acute trauma to the talus - extrusion or immediately non-viable talus.
- Revision hindfoot fusion for non-union and/or deformity
- Tibial plafond trauma
- Benign tumours/cysts/tumour-like conditions

Relative indications/contra-indications

The successful implantation of any 3-D implant requires an intact and healthy soft tissue envelope. This is an absolute pre-requisite.

There are two major groups of bony pathologies that fall into the realms of relative indications/contra-indications.

- Infection/contamination
- Charcot neuroarthropathy

The presence of infection remains a difficult challenge. If infection is contained within a bone, then resection of that bone (e.g. talus) could increase the likelihood of eradication of infection and further implantation could be considered. Equally, seemingly well-contained areas of infection determined by imaging may be amenable to resection and the void filled by an implant (e.g. an infected ankle replacement).

As is always the case, establishing the presence of infection by a preliminary biopsy is helpful. This can determine the pathological organisms and their sensitivity to anti-microbial agents. Following this, any infection can be treated by staged surgery. In the first stage, the area of infection can be resected and temporary void fillers, such as bone cement, can be used to maintain foot and ankle morphology. The cement, impregnated with appropriate antibiotics, provides a delivery system for local anti-microbial therapy. Alternatively, other calcium phosphate/sulphate delivery systems can be employed as part of the first stage or second stage reconstruction. In the latter case, cages can be impregnated with the antibiotic delivery system.

Second stage surgery can then be undertaken after monitoring bloods for inflammatory markers (ESR, CRP). Some centres advise frozen section input during the implantation surgery to be as certain as possible that the infection has been eradicated.

Eradication of intramedullary infection within the tibial canal is extremely tricky to achieve. Therefore, designing a 3-D implant that seats onto or into the tibial canal with a known history of intramedullary infection should be carefully considered and be the subject of a multi-disciplinary team decision.

Patient selection - general considerations

As in all aspects of surgery, choosing the patient for the procedure is complex and multi-factorial. The general biology of the patient should be uncompromised by systemic steroid therapy, general osteoporosis and a good vascular supply to the limb is essential. It is important for both consent and compliance with treatment that the patient's psychological profile is stable and that they have inherent mental capacity.

Consent

It is difficult to give absolute advice about this process given the realms of a patient-specific implant. In most scenarios regarding foot and ankle pathologies, the patient faces difficult treatment options and quite often, one of those options would be trans-tibial amputation. It would be highly unlikely that any surgeon would consent a patient for a procedure of this complexity based upon a single consultation and a multi-disciplinary approach is advisable. Multiple consultations are often required so that the patient appreciates the nature of the discussion that the treatment being proposed is bespoke, and that they understand that there is an element of risk and unpredictability in outcome.

It is advisable to perform pre-operative PROMS for comparison with post-operative progress. It may be useful to consent for the use of intra-operative photography.

Design and planning

Clinical examination needs to be very thorough. In planning any ankle arthroplasty or hindfoot fusion, the presence of proximal deformity in the lower limb needs to be appreciated. Within the foot and ankle all deformity should be assessed for flexibility versus fixity. This is important because the engineers dealing with CT images acquired from the patient lying on a CT gantry will not account for your clinical findings and your clinical acumen. Weight bearing plain radiographs and clinical photographs aid in the design process meeting. In addition, it may be prudent to have a second, experienced surgical colleague contribute to the WebEx planning meeting for their thoughts, ideas and provision of governance for the process.

During the planning meeting, the engineers need to know the intended surgical approaches and therefore accurate knowledge of previous surgical incisions is mandatory.

Textbook surgical approaches still form the basis of decision making but factors such as previous surgical scars and soft tissue contractures play an important part in optimising access. Considerations would include:

- Use old incisions whenever possible
- Avoid approaching through skin that will be stretched after deformity correction
- Err on the side of smaller implants that may cause less stretch to the soft tissue envelope
- Be wary of neurovascular structures

Surgical approaches

In general, the lateral, trans-fibular approach affords safe access to the distal tibia, talus and calcaneus.

This can be achieved by surgeon preference but acetabular reamers to the distal fibular metaphysis create bone graft but the old RAF technique of a sagittal cut through the distal fibula to create a superficial part on a soft-tissue hinge that provides a vascularised lateral bone block to fuse against the implant to encourage greater bone-implant integration. The deep fibula fragment can then be morcellised into graft. Dealing with seating the implant on the medial bone is slightly compromised through this approach. However, this approach is often complemented by being able to lie the patient in a full lateral position that allows comfortable, seated operating for a potentially long case.

The anterior approach provides less good access to the back of the ankle joint but does allow you to easily remove a previous TAR. It is also the approach of choice for resection of the whole talus and implantation of a total talar replacement. Supplementary medial approaches can be useful for removing loose bodies and sculpting of the medial malleolus.

Imaging

The minimum imaging requirements for foot and ankle procedures using this technology include standing plain radiographs of both the foot and the ankle. It is necessary for standing imaging because this provides better appreciation of deformity. Some clinicians may also want Cobey or Saltzmann views to better assess hindfoot alignment. For the planning process, CT with 1mm bone cuts of both feet and ankle will provide optimal information about the pathology but clinicians need to be aware that CT images acquired with the patient lying down may not be a true representation of any deformity. In future, standing CT images may prove much more useful.

Operative planning in general

Microbiology

In any infected, contaminated or potentially infected case, there may be the need for input from colleagues in microbiology and histology. In a staged procedure, this obviously involves taking accurate tissue samples in the first stage, but may involve taking intra-operative frozen section specimens at the second stage. The use of antibiotic delivery systems such as Cerament™ and Stimulan™ should be considered.

Surgical assistance & theatre support


It is always useful to have experienced assistance during these complex procedures and dual operating with a Fellow or Consultant colleague is advisable. Equally, representatives from the implant company or companies supplying antibiotic delivery systems should be present to provide support for your theatre scrub team. Ideally, have senior, experienced scrub staff rostered for the case. Allow plenty of time for the procedure and limit potential distractions such as on-call commitments!

Useful specific kit adjuncts

A spinal bone mill (eg Noviomagus™) is far superior to a standard bone mill used in hip surgery for morcellising femoral head allograft. The spinal bone mill creates a finer grade of graft that can be more easily packed into the interstices of the 3-D truss.

The availability of a high-speed burr allows detailed sculpting of the bone surfaces and especially useful in the fine tuning of the bone surfaces in the deepest parts of the surgical wound. For instance, on performing a lateral, trans-fibular approach, the burr is very useful in fashioning the deep surfaces of the medial malleolus.

Carefully consider the use of tourniquet in these cases with regard to the consequences of prolonged tourniquet inflation times.



CASE EXAMPLE 1

A 61-year old female presented with a 18-month history of unremitting pain and swelling in her left ankle. All weight-bearing activity exacerbated her pain and for many months she experienced interrupted sleep because of these symptoms.

There was no history of preceding history of injury to her ankle and she had no risk factors for developing avascular necrosis of the talus. Examination revealed a swollen hindfoot, a mildly planovalgus foot shape with notably irritable ankle and subtalar joints. The planovalgus deformity was supple and correctable. The range of motion of the ankle, subtalar and talonavicular joints was free of crepitus, but reduced at the extremes of the arc of motion and intrinsically the motion of all joints were sore. Plain standing radiographs revealed dense, sclerotic appearances to the body of the left talus but no frank evidence of significant collapse of the body of the talus or arthropathy at the tibio-talar, subtalar or talo-navicular joints (Figures 1 & 2). Further imaging was required to define the extent of the pathology and to guide treatment. MRI imaging was used to ascertain the extent of the AVN and CT was used to assess for arthrosis. The MRI images showed involvement of the whole of the talus with intra-osseous cyst formation and fracture lines extending into the talo-navicular joint and middle facet of the subtalar joint and the CT provided more pathoanatomic detail (Figure 3). Together with the CT images, it was apparent that there were no degenerative changes in any of the articulations with neighbouring bones. There was no evidence of significant collapse of the body of the talus (Figure 4).

Figures 7a & 7b Plain radiographs of the left ankle show sclerosis within the body of the talus but reasonable health of the ankle and subtalar joints. Note the considerable soft tissue swelling.

Figure 7c Sagittal CT slice showing the clear destruction of the body of the talus and confirming the lack of arthrosis at any of the peritalar joints.

Diagnosis: Global Talar AVN

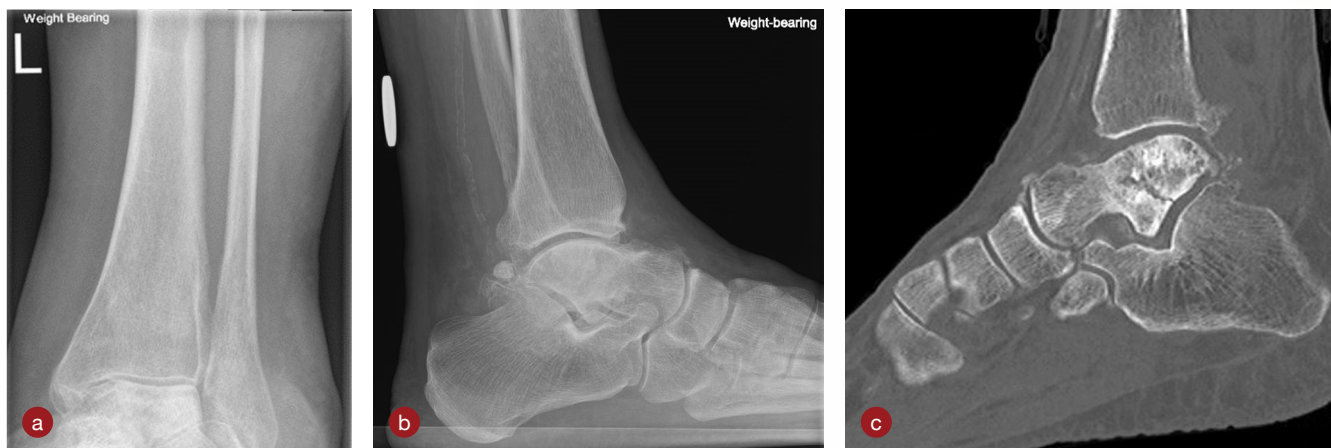

Figure 7:
Plain radiographs (a & b) and sagittal CT slice (c) together demonstrating sclerosis, talar body collapse and fracture lines as a result of AVN

Design objective:

Fully articulating, bespoke total talus replacement (TTR)

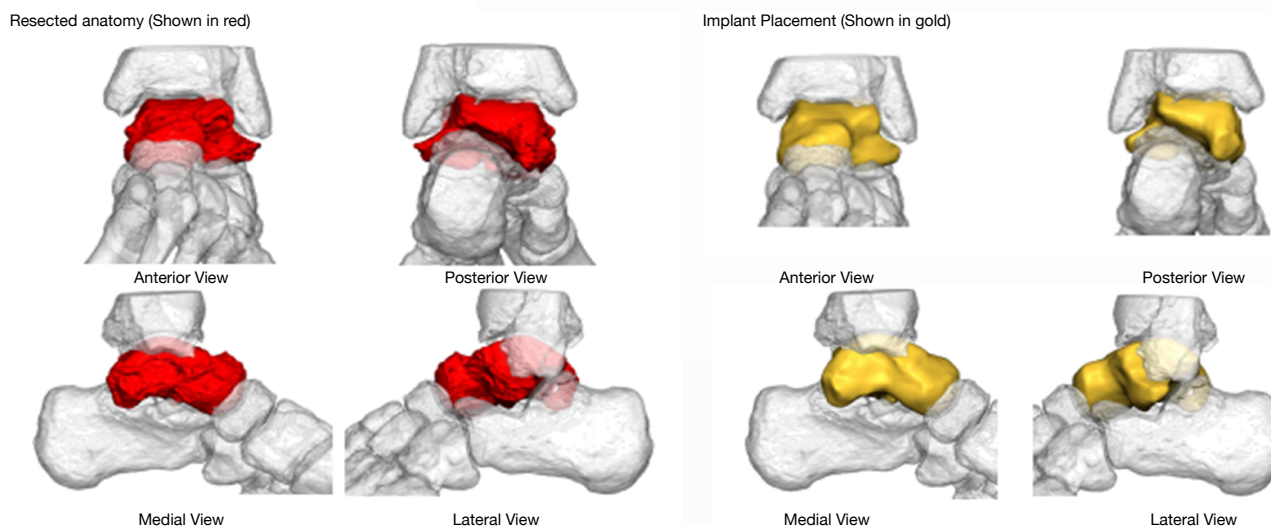


Figure 8:
Pre-operative treatment plan outlining resected native talar bone and optimal placement of designed implant

Surgical incision

Standard anterior approach to the ankle permitting visualisation of the talonavicular joint.

Talar resection

With a saw, the neck of the talus was osteotomised allowing the talus to be resected in a piecemeal manner using osteotomes and rongeurs. With removal of the talus, each articular surface can then be inspected for wear. In this case, each surface was in good health.

Trialling

The manufacturing design team provided 2 sizes of the desired implant - one that fits to scale with the CT images and one slightly smaller in the medio-lateral and superior-inferior dimensions of the body of the talus. In this case, two trial implants were made to allow assessment of optimal prosthesis size. The small trial was palpably too slack in the mortise when all joints were mobilised and so the larger implant was selected after superior feel from testing the larger trial (Figure 9).

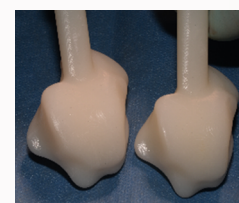

Figure 9:
The two trial implants made from medical grade plastics

Implantation

The implant was readily inserted by traction to distract the ankle and application of plantarflexion to the foot. Subsequent on table assessment revealed a clearly stable talus. Wound closure proceeded in the usual fashion.

Post-operative regime

The patient is placed in a backslab cast and forbidden to bear weight for 2 weeks to allow the surgical wounds to settle. Thereafter, weight bearing commences wearing a protective walking boot for a further 4 weeks. The patient is shown ankle and subtalar range of motion exercises. At week six, the boot is removed and post-operative X-rays are performed (Figure 10). Thromboprophylaxis is prescribed according to surgeon preference.

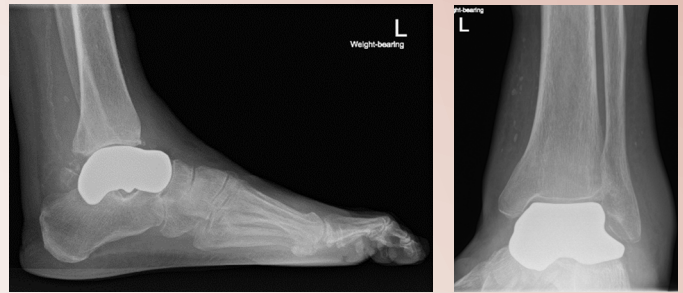


Figure 10:
6 Weightbearing radiographic views of the TTR in situ

CASE EXAMPLE 2

A 57-year old female presented with a 24-month history of unremitting pain in her left ankle. There was no history of trauma and no other causes for AVN could be detected in her history. All weight-bearing activity exacerbated her pain and she had had interrupted sleep because of pain.

Examination revealed swollen hindfoot with reasonable ankle range of motion but an irritable and stiff subtalar joint. Her soft tissue integumen was in good health with normal neurovascular assessment. There was no significant deformity in any plane.

Plain standing radiographs revealed dense, sclerotic appearances to the body of the left talus with some collapse of the body of the talus and a degree of subluxation of the talonavicular joint (Figure 11). From the plain radiographs alone, it was clear that the diagnosis was avascular necrosis of the body of the talus. The patient was not keen to try further non-operative measures such as stronger analgesics and a rigid ankle-foot orthosis and was keen to discuss surgical options for treatment. Therefore, further imaging was required to define the extent of the pathology and to guide treatment. CT imaging was requested including contralateral CT views of the unaffected hindfoot in case of planning for a Meshworks custom implant.

CT imaging revealed the true extent of collapse of the body of the talus but was reassuring in determining that the ankle joint was not arthritic but there was a clear cyst lying adjacent to the posterior facet of the calcaneus (Figure 12).

Diagnosis: Global AVN with neighbouring joint arthrosis - Subtalar Joint

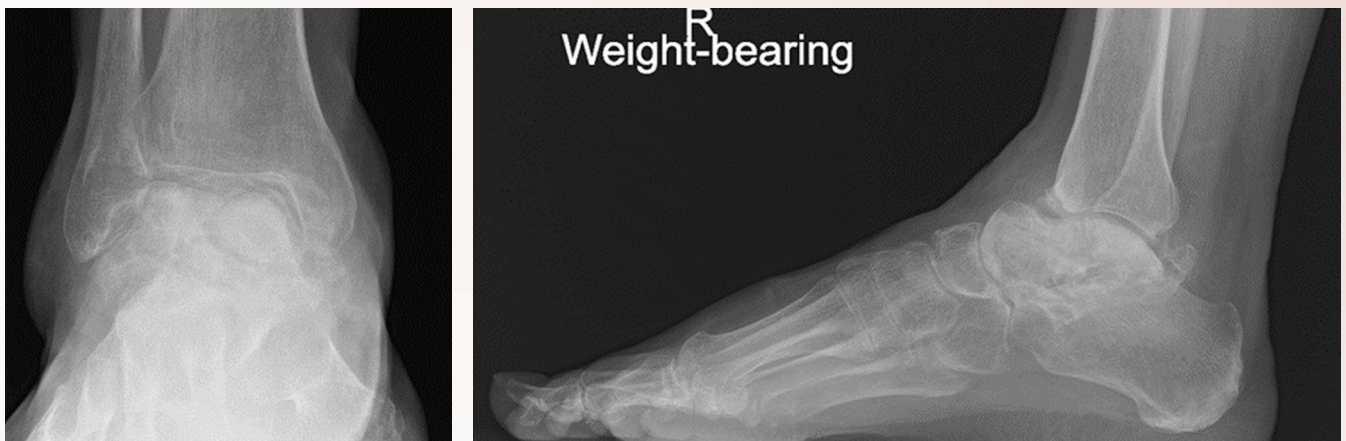

Figure 11:
Pre-operative x-ray views showing collapse of the body of the talus and a rotational and apparent dorsiflexed talus affected by AVN. The subtalar joint is not readily visible on the lateral radiograph

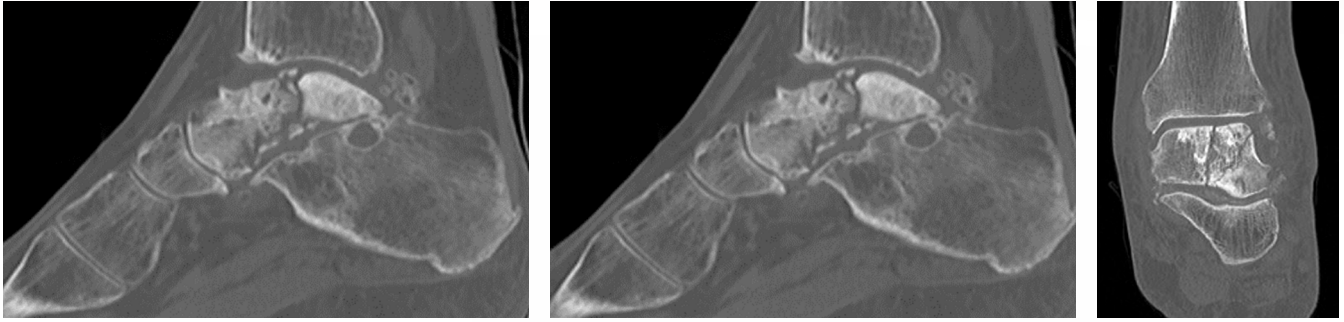


Figure 12: Pre-operative CT imaging reveals cyst formation and disease of the posterior subtalar joint together with sclerosis and fragmentation of the whole talus (global AVN)

Design objective:

Total talus replacement bespoke implant with subtalar fusion surface and fixation capabilities at fusion site.
(Figure 13a through to 13e)

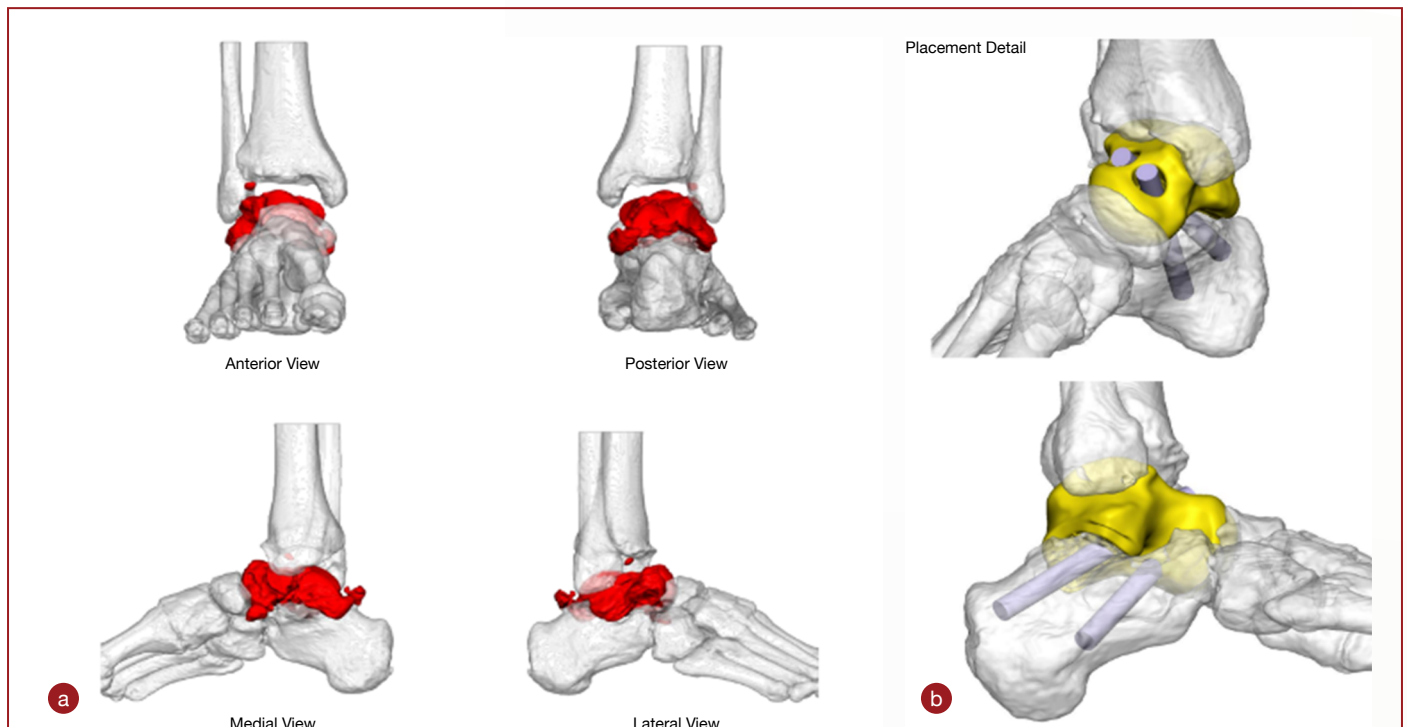


Figure 13a and 13b: Pre-operative treatment plan outlining resected native talar bone and optimal placement of designed implant with planned lag screw compression across the posterior facet of the subtalar joint

Implant Details
Implant Height = Nominal

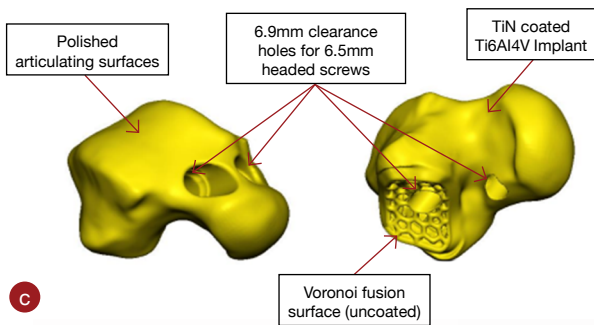


Figure 13c: Shows the design features of the definitive implant

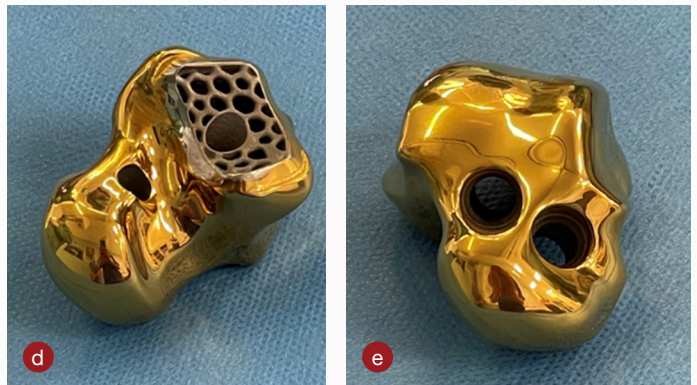

Figure 13d & 13e: Illustrate those features on the definitive implant

Surgical incision

Standard anterior approach to the ankle permitting visualisation of the talonavicular joint.

Talar resection and Subtalar joint preparation

With a saw, the neck of the talus was osteotomised allowing the talus to be resected in a piecemeal manner using osteotomes and rongeurs (Figure 14a). With removal of the talus, each articular surface can then be inspected for wear.

The posterior facet of calcaneus component of the subtalar joint surface is prepared by denuding the articular surface using flexible chisels and osteotomes to reveal subchondral bone.

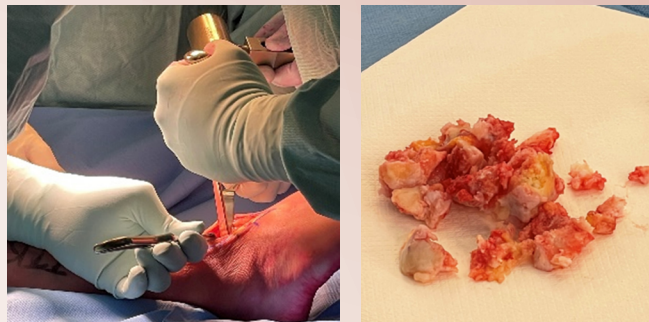


Figure 14a & 14b:
Removal of native talus and resected talus post removal

Trialling

The manufacturing design team provided 2 sizes of the desired implant - one that fits to scale with the CT images and one slightly smaller in the medio-lateral and superior-inferior dimensions of the body of the talus. In this case, the smaller trial and implant were 2mm smaller in the above dimensions compared to the implant/trial designed to fit to scale. The large trial did not easily insert due to the resultant soft tissue stiffness on the patient and so the smaller implant was selected after superior feel from testing the smaller trial.

Grafting and implantation

Bone graft was used from the resected bone and inserted into the truss interstices (Figure 15a). The implant is then inserted and the subtalar joint compressed with the pre-planned lag screws by passage of the K-wire (Figure 15b) and over drilling. The cannulated screw is then passed across the implant to lag the calcaneus to the implant.

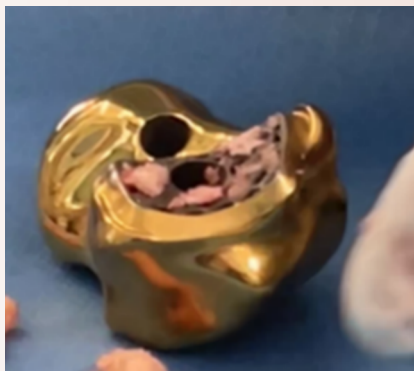

Figure 15a:
Autograft being inserted into the truss interstices of implant on the fusion surface opposing the posterior facet of the calcaneus

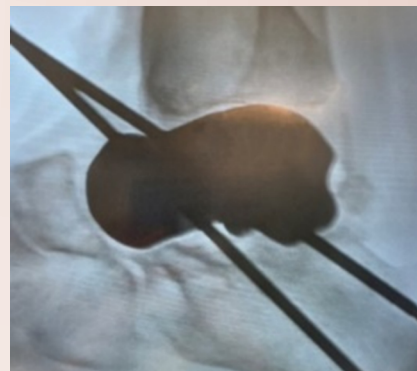

Figure 15b:
Intra-operative x-ray of definitive implant in-situ and lag screw k-wires inserted

Final AP and lateral Intra-operative X-ray views

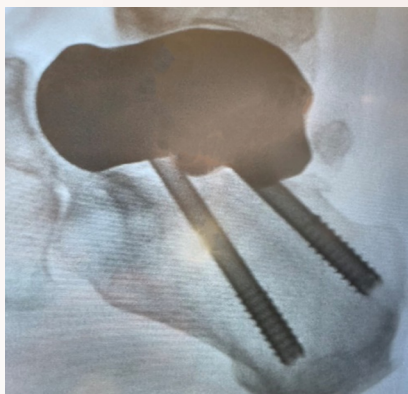
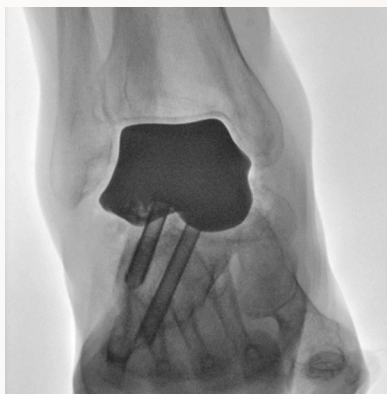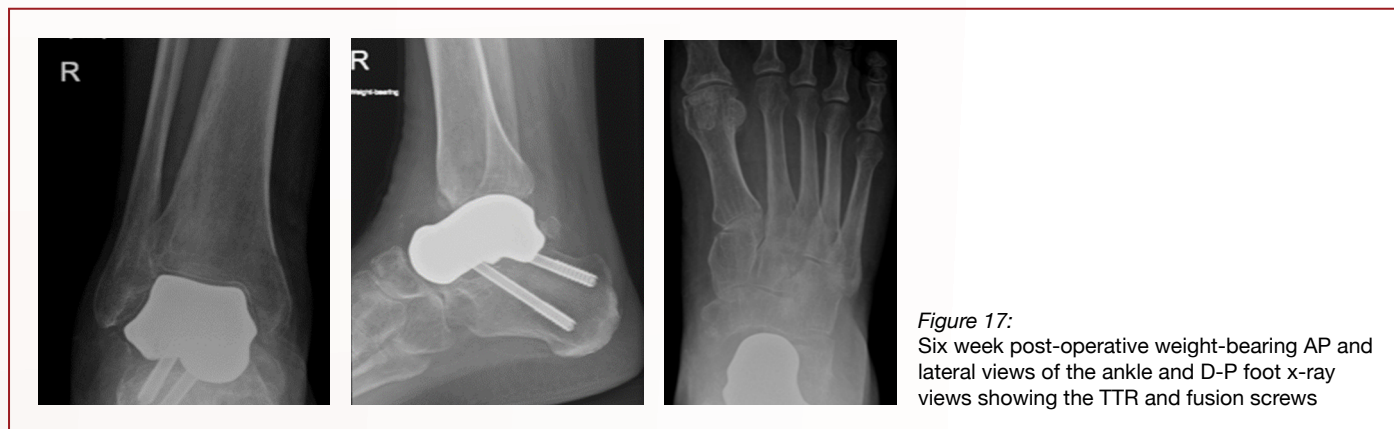


Figure 16:
Final intra-operative x-rays. AP view and lateral view

Post-operative regime

The patient is managed as if a primary subtalar fusion. Therefore, the patient is placed in a backslab cast and forbidden to bear weight for 2 weeks to allow the surgical wounds to settle. They are then placed in a further cast and are restricted from weight-bearing for a further four weeks. Thereafter, weight bearing is permitted within a protective walking boot for a further 6 weeks. Thromboprophylaxis is prescribed according to surgeon preference.

Six week post-operative weight-bearing AP, lateral and axial X-ray views



CASE EXAMPLE 3

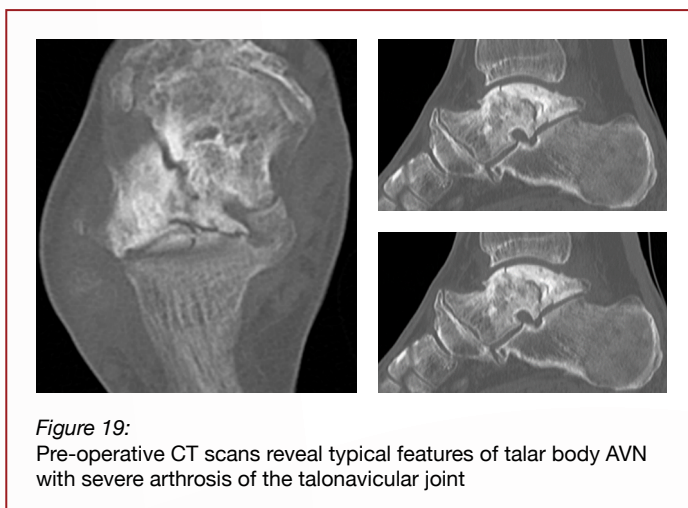
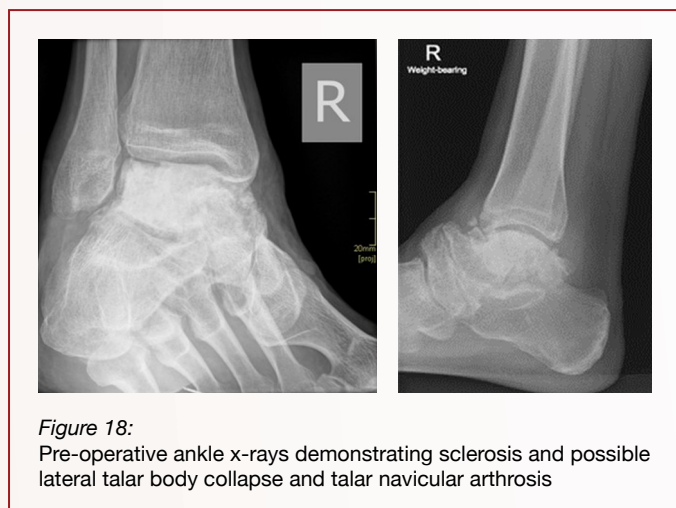A 52-year old male presented with a 20-year history of increasing pain in his right ankle. There was a vague history of trauma during a soccer match 20 years ago, but never any confirmed bony injury. He was a smoker and had more than national guidance weekly intake of alcohol. The pain had meant he had to stop working in a factory.

Examination revealed swollen hindfoot with reasonable ankle range of motion but a clear palpable osteophyte overlying the talonavicular joint and stiffness within this joint. His subtalar joint appeared to move normally. His soft tissue integument was in good health with normal neurovascular assessment. There was no significant deformity in any plane.

Plain standing radiographs revealed dense, sclerotic appearances to the body of the right talus consistent with the diagnosis of AVN (Figure 18). There was minimal collapse of the body of the talus but severe arthritic changes to the talonavicular joint. The patient was not keen to try further non-operative measures such as stronger analgesics and a rigid ankle-foot orthosis and was keen to discuss surgical options for treatment. Therefore, further imaging was required to define the extent of the pathology and to guide treatment. CT imaging was requested including contralateral CT views of the unaffected hindfoot in case of planning for a Meshworks custom implant.

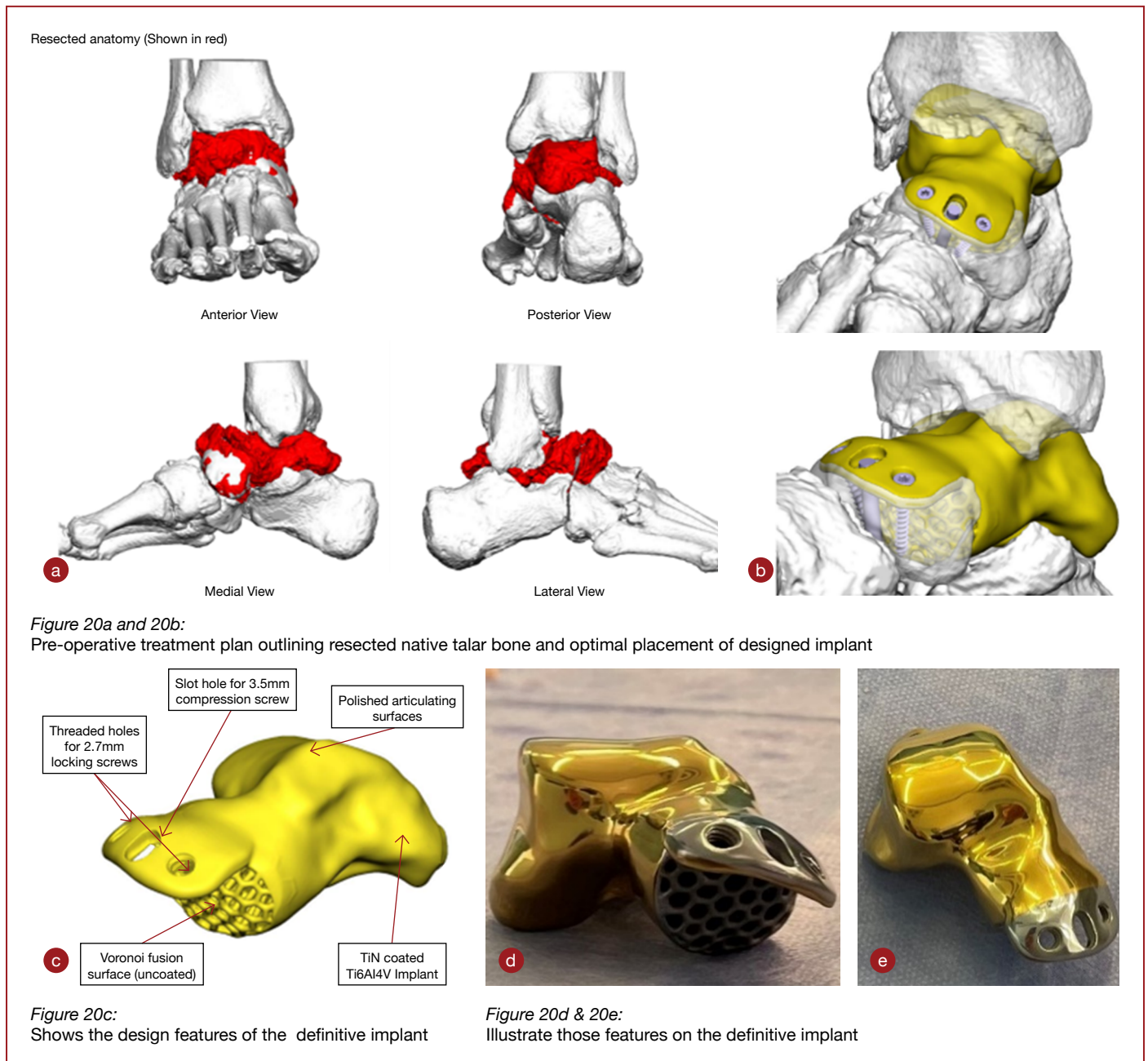
CT imaging confirmed the minimal collapse of the body of the talus and that the ankle and subtalar joints were not degenerate. The talonavicular arthrosis was clearly visible (Figure 19).

Diagnosis: Global AVN with neighbouring joint arthrosis - Talonavicular joint



Design objective:

Total talus replacement bespoke implant with talonavicular fusion surface and fixation capabilities at fusion site (Figures 20a through to 20c).



Surgical incision

10 cm anterior approach to the ankle extending distally to allow access to the whole dorsal surface of navicular.

Talar resection and Talonavicular joint preparation

With a saw, the neck of the talus was osteotomised allowing the talus to be resected in a piecemeal manner using osteotomes and rongeurs (Figure 21a). With removal of the talus, each articular surface can then be inspected for wear. Care was taken to resect all of the significant osteophytes from the navicular. In this case, the concave surface of the navicular was denuded of articular surface using a curette and fine osteotomes to reveal subchondral bone.

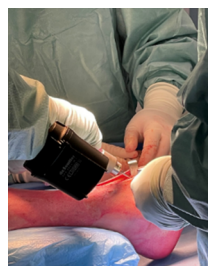

Figure 21a:
Using a saw to osteotomise the neck of talus

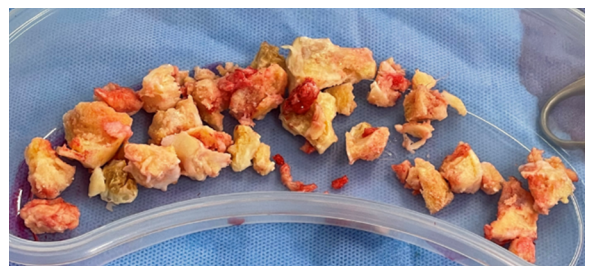
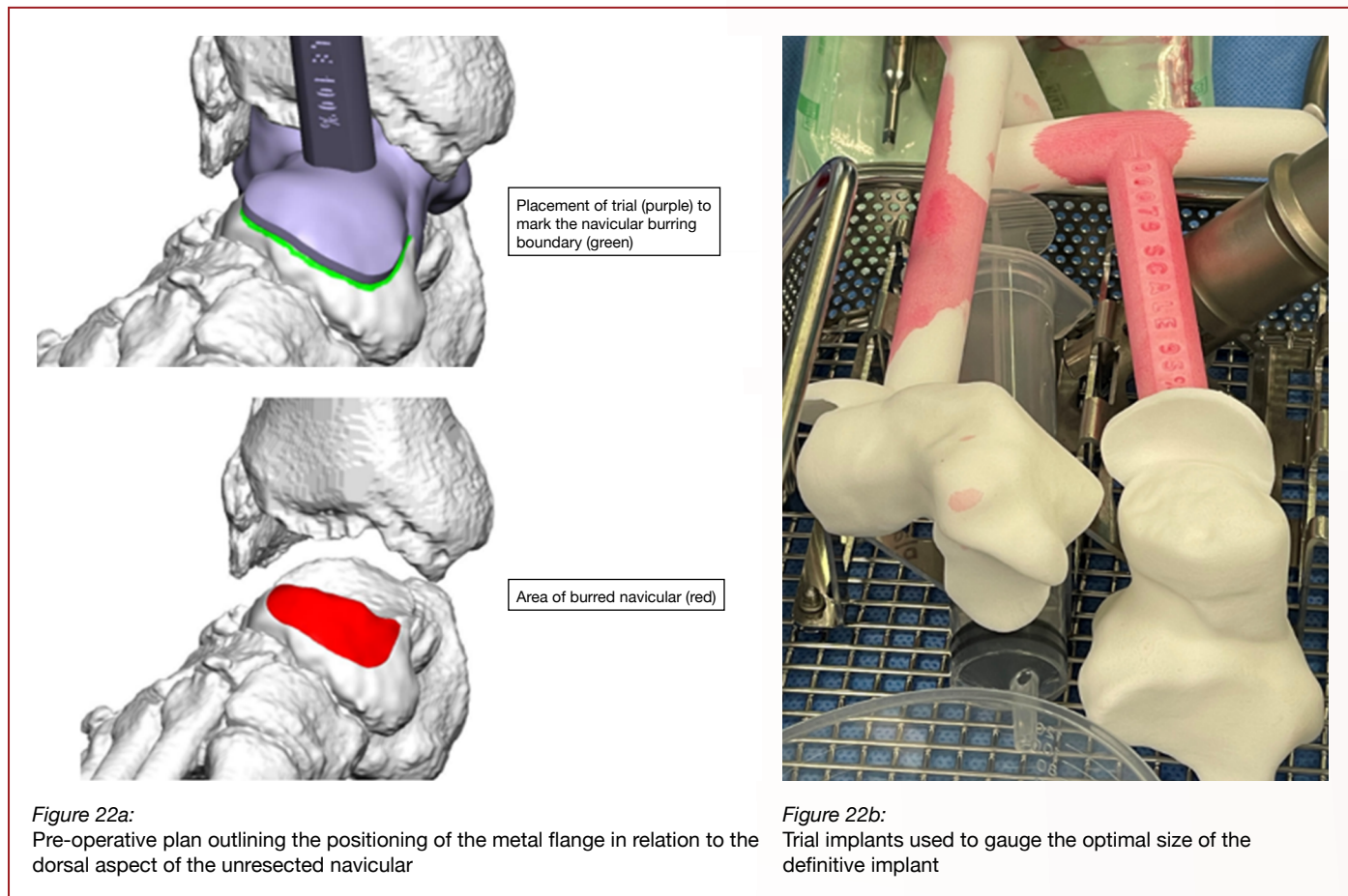


Figure 21b:
Resected native talus once removed from patient

Surface preparation for implant flange and trialling of implant

With the trial in situ, a marker pen was used to mark out the position of the dorsal flange covering the navicular. This allowed gentle burring of the dorsal navicular cortex to accommodate the flange as flush as possible.

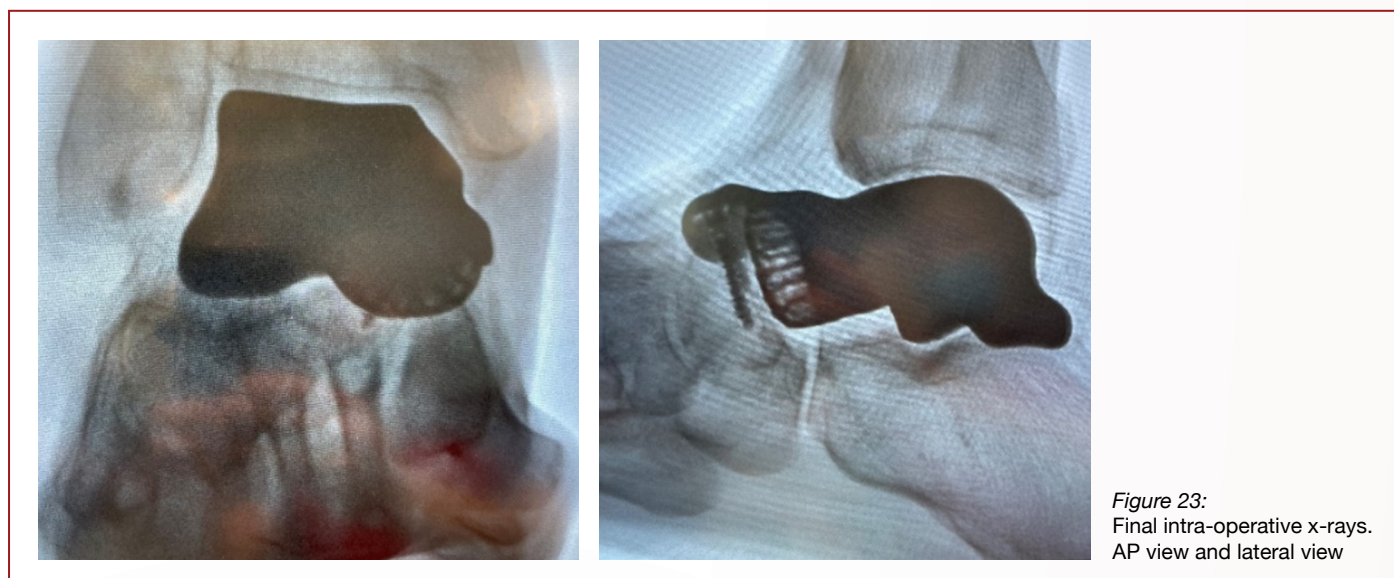

Grafting and implantation

Bone graft was used from the resected bone and inserted into the truss interstices. Once the implant was prepared, it was then placed into the void by traction and application of plantarflexion to the foot. In this case, a non-locking screw was inserted into the oval machined slot to apply compression across the TNJ. Once achieved, locking screws were inserted into the machined locking holes for further fixation.

Final AP and lateral Intra-operative X-ray views

Final Intra-operative x-rays. AP view and lateral view.



Post-operative regime

The patient is managed as if a primary talonavicular fusion. Therefore, the patient is placed in a backslab cast and forbidden to bear weight for 2 weeks to allow the surgical wounds to settle. They are then placed in a further cast and are restricted from weight-bearing for a further four weeks. Thereafter, weight bearing is permitted within a protective walking boot for a further 6 weeks. Thromboprophylaxis is prescribed according to surgeon preference. Plain radiographs are taken at 6 weeks (Figure 24).

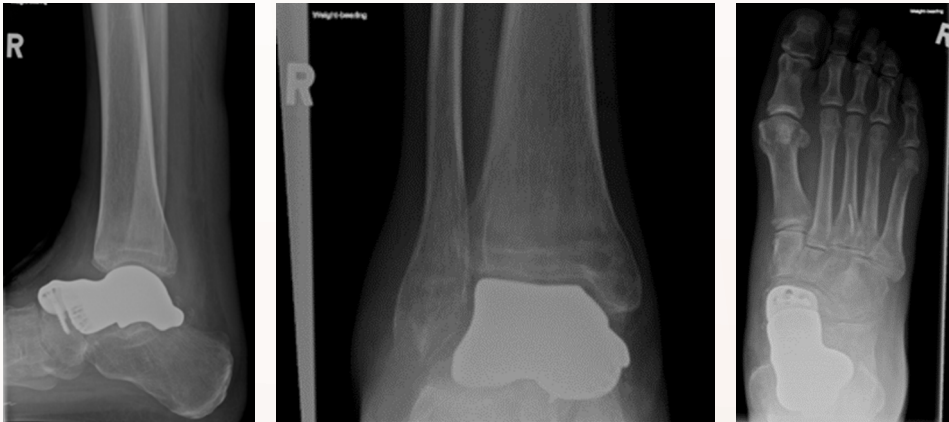

Figure 24:
Plain weightbearing radiographs of the foot and ankle at week 6 post-op

CASE EXAMPLE 4

A 34-year old female presented with a 3-year history of increasing pain in her left ankle. There was a history of significant trauma as she was thrown from her horse landing awkwardly sustaining a closed fracture of the neck of talus. She underwent open reduction and internal fixation through two incisions utilising anteromedial and anterolateral approaches. She had no post-operative wound problems but she experienced increasing degrees of pain such that when her talus appeared to undergo early collapse, her metalwork was removed leaving behind a retained screw thread in the head of the talus. In spite of this intervention, she became dependent upon two crutches for weight bearing. She was otherwise fit and well.

Examination revealed swollen hindfoot with a clear fixed equinovarus hindfoot deformity with pain on moving the ankle and subtalar joints. The surgical scars had healed well. There was no neurovascular deficit.

Plain standing radiographs revealed an un-united medial malleolar fracture fragment, fragmentation of the body of the talus with medial dome collapse together with incongruent ankle and subtalar joints (Figure 25a). CT imaging was requested including contralateral CT views of the unaffected hindfoot in case of planning for a Meshworks custom implant.

CT imaging confirmed the diagnosis of AVN with collapse of the body of the talus, sparing the neck of the talus. Both the ankle and subtalar joints were degenerate (Figure 25b).

Diagnosis: Partial AVN with neighbouring arthrosis - Ankle and Subtalar joints

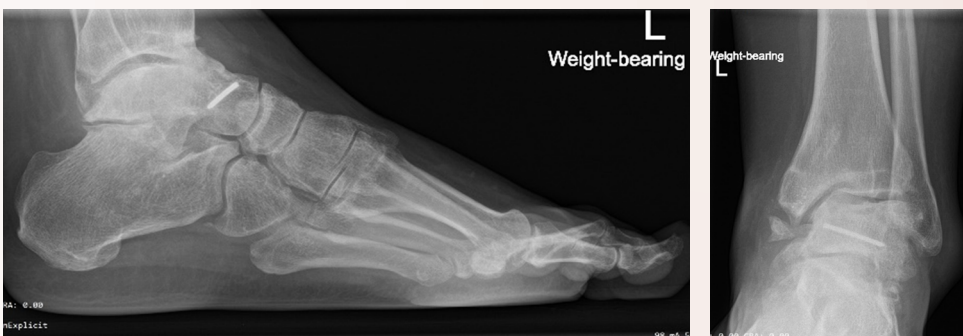

Figure 25a:
Pre-operative x-rays, AP and lateral views demonstrating AVN with collapse of the body of the talus, an un-united medial malleolar fracture fragment and an apparent varus deformity owing to disproportionate collapse of the medial aspect of the talus. Note the retained screw thread that was not retrieved at the time of removal of the metalwork used to fix the original fractured talus

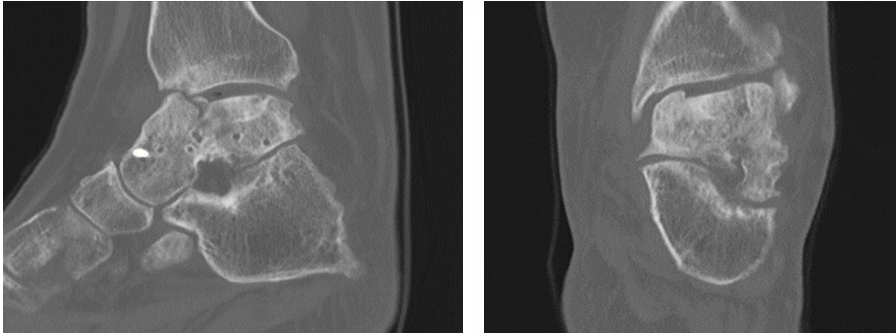


Figure 25b: Pre-operative CT scans provide further information and suggest that the head and neck of the talus remain viable thus making this a case of partial AVN of the talus

Design objective:

Bespoke Fusion cage with anatomic calcaneal and tibial interfaces, retaining the native talar head. The planning aimed to retain the broken screw thread by accurate planning of a custom saw capture jig to be applied to the lateral body of the talus.

Cutting Guide Detail

Note: This guide is designed for a 1mm Saw Blade.

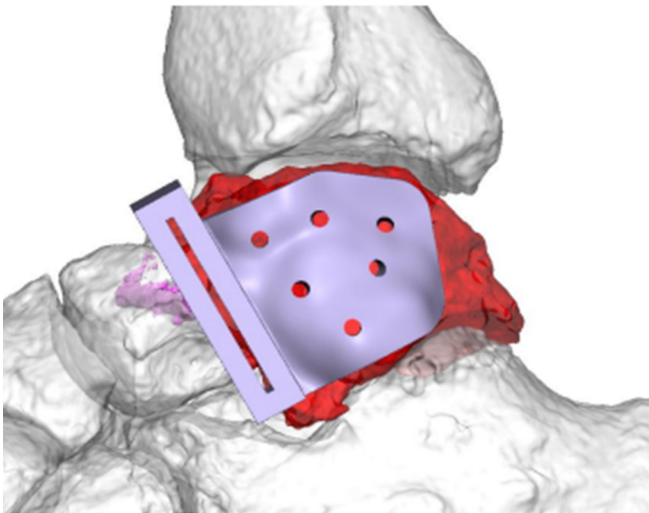


Figure 26a: Pre-operative plan outlining where anatomically contoured cutting jig was planned to sit on native talus. Note the holes provided to secure the jig with K-wires

Implant Placement (Shown in grey)

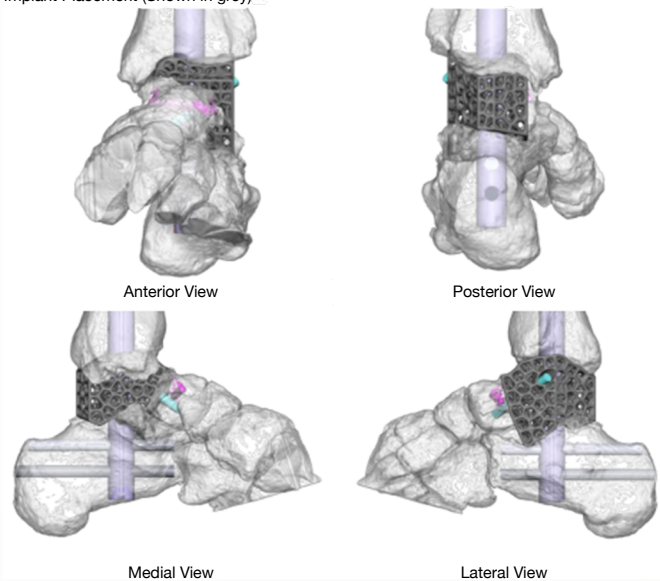


Figure 26b: Pre-operative treatment plan outlining optimal placement of designed implant and ancillary fixation devices

Surgical incision

A lateral incision along the longitudinal axis of the fibula, with an anterior curve distally, to allow access to the lateral process of the talus and posterior facet of the subtalar joint.

Resection of talar body

Anatomically contoured cutting jig (Figure 27) was inserted onto the lateral talar neck, which allowed accurate resection of the talar body. Once the neck cut had been made the body of the talus could be resected piecemeal using saws, osteotomes and rongeurs.

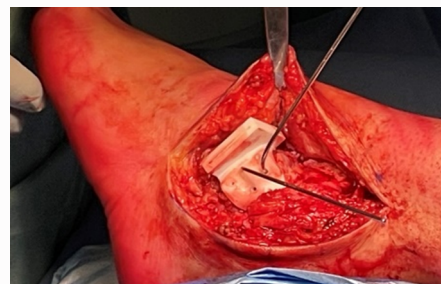


Figure 27: Anatomically contoured cutting jig inserted on the lateral talar neck

Trialling and preparation of ancillary fixation

The manufacturing design team provided 3 sizes of the desired implant - one that fits to scale with the CT images and two that can either be slightly smaller or bigger in the superior-inferior dimension. In this case, the 'planned' size was the best fit and corrected the pre-operative deformity.

All three trials have a 14mm cannulated feature to allow preparatory steps of the surgical technique of the intramedullary nail, to be inserted through the implant to for definitive fixation.

Once the trial was in situ, preparation for IM nailing proceeds in a standard manner: the guide wire can be passed through the trial and then sequential reaming to accommodate the nail implant (Figure 28).

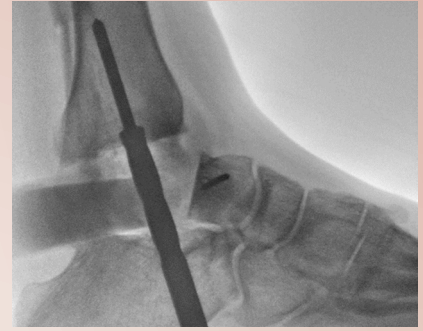

Figure 28:
Intra-operative x-ray with trial in desired implant position during reaming of the tibial canal

Implantation

Once the appropriate size was established through trialling, the implant was filled with bone graft. Once the implant was prepared, it was then placed into the void and secured with the Oxbridge hindfoot arthrodesis nail. The nail was inserted and locked dynamically in the tibia and statically in the calcaneus. The remaining talar head is then lagged onto the implant through a pre-planned screw hole using a partially threaded 4mm screw.

The RAF Technique: The superficial fibula is hinged back into position and temporarily held with K-Wires. Small cannulated screws can then be implanted to lag the bony flap against the lateral distal tibia. (Figure 29)

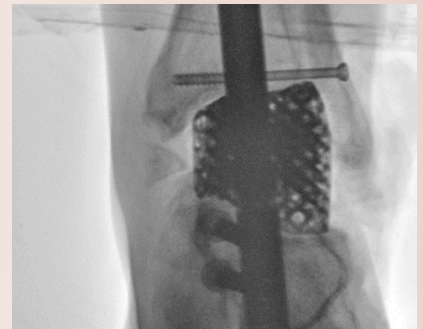


Figure 29:
Intra-operative x-ray showing definitive Meshworks implant, IM nail in-situ and completion of RAF technique

Final AP and lateral Intra-operative X-ray views

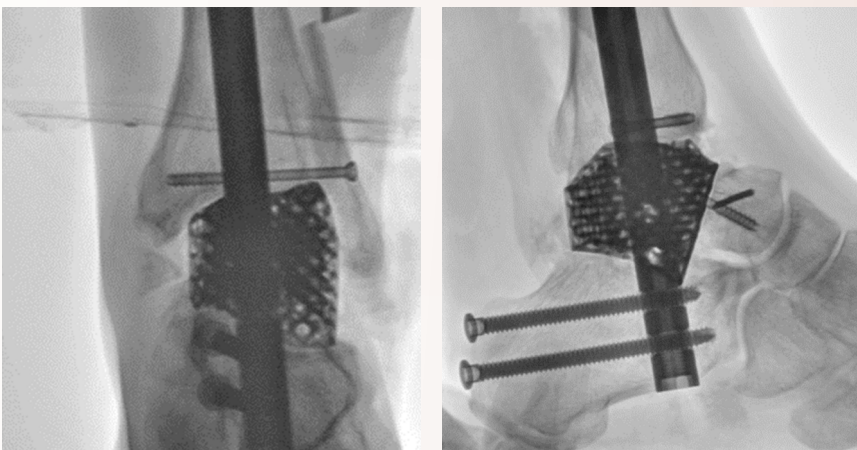


Figure 30:
Final AP and lateral Intra-operative X-ray views

Post-operative regime

The patient is managed as if a primary tibiototalcalcaneal fusion. Therefore, the patient is placed in a backslab cast and forbidden to bear weight for 2 weeks to allow the surgical wounds to settle. They are then placed in a further cast and are restricted from weight-bearing for a further four weeks. Thereafter, weight bearing is permitted within a protective walking boot for a further 6 weeks. Thromboprophylaxis is prescribed according to surgeon preference.

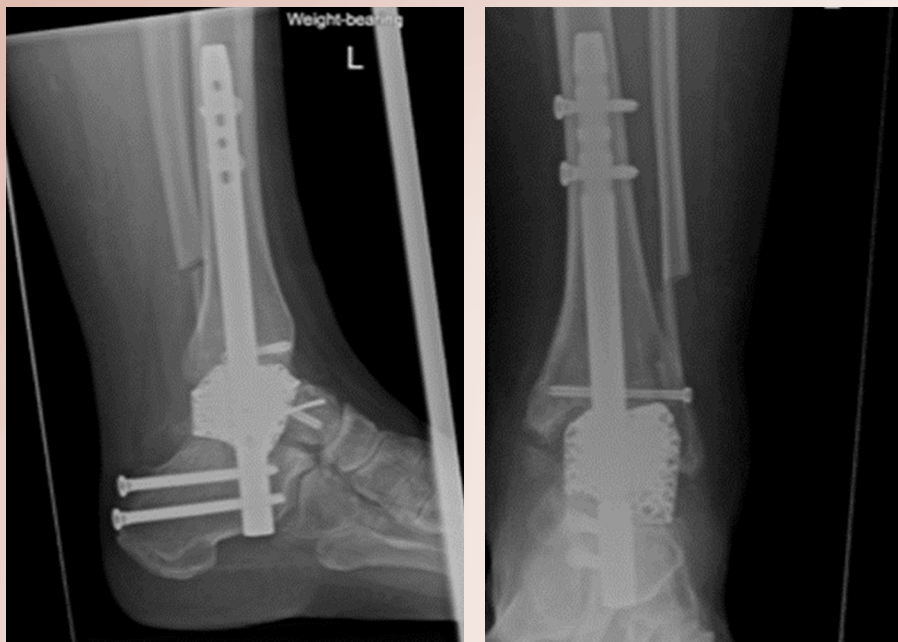


Figure 31:
Plain weightbearing radiographs of the foot
and ankle at week 6 post-op

REFERENCE LIST

1. Mulfinger GL, Trueta J. The blood supply of the talus. J Bone Joint Surg. 1970;52B:160–167.
2. Adelaar RS, Madrian JR. Avascular necrosis of the talus. Orthop Clin North Am. 2004;35:383–395
3. Miller AN, Prasarn ML, Dyke JP, Helfet DL, Lorich DG. Quantitative assessment of the vascularity of the talus with gadolinium-enhanced magnetic resonance imaging. J Bone Joint Surg Am. 2011;93(12):1116–1121.
4. Prasarn ML, Miller AN, Dyke JP, Helfet DL, Lorich DG. Arterial anatomy of the talus: a cadaver and gadolinium-enhanced MRI study. Foot Ankle Int. 2010 Nov;31(11):987-93
5. Delanois RE, Mont MA, Yoon TR, Mizell M, Hungerford DS. Atraumatic osteonecrosis of the talus. J Bone Joint Surg Am. 1998 Apr;80(4): 529-36

OrthoSolutions

Group

Advancing Foot & Ankle Care

OrthoSolutions UK Limited West Station Business Park,
Spital Road, Maldon, Essex. CM9 6FF, United Kingdom
www.orthosol.com

Scan here to know more



Over  years of
excellence 