

# Consensus of the 4<sup>th</sup> Round Table Budapest June 2014

*Tom Ball FRCS (Tr & Orth)*

*Phil Vaughan FRCS (Tr & Orth)*

*Dishan Singh FRCS (Orth)*



***Complications in Foot and Ankle Surgery***

## **Preface**

*The 1<sup>st</sup> Round Table meeting was held in Padua in June 2011, followed by the 2<sup>nd</sup> meeting in Paris in June 2012 and the 3<sup>rd</sup> meeting in Barcelona in June 2013. This year's meeting in Budapest has once again not followed the usual orthopaedic meeting format where faculty members lecture to delegates. As always, the meeting is unique in that all participants have an equal input to review the literature and present their individual experience on a topic - with ample time for an informal discussion of the subject in a relaxed setting.*

*In 2014, we have chosen to discuss the topic of dealing with complications we may encounter in our clinical practice. Discussion of complications is rarely addressed in the foot and ankle literature or at meetings where more time is spent on discussion of success. To quote Mercer Rang, the surgeon grieves for the patient who has suffered a complication under his or her care and the surgeon's whole outlook on a particular problem may be altered. Yet, a surgeon has to formulate a logical plan for investigating and treating the encountered complication.*

*Phil Vaughan and Tom Ball were responsible for recording opinions and capturing the essence of the debates, many of which resulted in consensus being reached on areas of foot and ankle practice. This booklet collates the literature review and the views of all those who participated.*

*This booklet does not represent Level I evidence derived from prospective randomized controlled trials but represents the compilation of the combined experience of 35 British orthopaedic surgeons as well as a much valued input from Chris Coetzee from the United States of America and Michael Stephens from Ireland.*

*I hope that you will find something of use and relevant to your own practice.*

*Dishan Singh, MBChB, FRCS, FRCS (Orth)*

*Consultant Orthopaedic Surgeon*

*Royal National Orthopaedic Hospital*

*Stanmore, United Kingdom*

October 2014

# Consensus of the 4<sup>th</sup> Round Table Budapest 2014

## Complications in Foot & Ankle Surgery

*Tom Ball*

*Phil Vaughan*

*Dishan Singh*



Convenors:

Mr Dishan Singh

Mr Paul Cooke

Mr Nick Geary

Mr Fred Robinson

Hosts:

Ortho Solutions

---

Distilled in this document are the thoughts and opinions with consensus where possible of 35 Orthopaedic Foot and Ankle Consultant Surgeons who gathered from across the United Kingdom, Ireland and USA. Though eminence rather than true evidenced based medicine this represents the concepts of over 200 years of combined experience. A basis of invited lectures introduced open and frank discussion from which consensus was sought. The statements herein only represent those of individuals and no claim is made that they are irrefutable. All the percentage figures quoted represent the proportion of the surgeons present who voted on the subject in discussion.

**Session 1****GENERAL POST-SURGICAL COMPLICATIONS**

Deep vein thrombosis	Dishan Singh
Infection/ wound healing	Simon Platt
Delayed union/ non-union	Chris Coetzee
Malunion	Paul Cooke
Nerve injury	Michael Stephens
Chronic Pain including RSD	Andy Molloy

**Session 2****HALLUX VALGUS SURGERY**

Hallux varus	David Williamson
Recurrence	Mark Herron
Avascular necrosis metatarsal head	Mark Davies
Transfer metatarsalgia	Anand Pillai

**Session 3****HALLUX RIGIDUS SURGERY**

Failed cheilectomy	Stephen Bendall
First MTP joint malunion/non-union	Ben Rudge
Failed first MTP joint Keller's or arthroplasty	Tim Williams

**Session 4****LESSER TOE SURGERY**

Floating toe/stiff MTPJ	Amit Amin
Short or floppy lesser toes after surgery	Rick Brown
Non-union, malunion, AVN after Weil or DMMO	Fred Robinson

**Session 5****TENDON, LIGAMENT & OCD SURGERY**

Achilles tendon rerupture	Matthew Henderson
Wound healing after Achilles surgery	Callum Clark
Achilles too long or too short	Sam Singh
Persistent flat foot after tib post reconstruction	Chris Coetzee
Problems after peroneal tendon surgery	Michael Stephens
Failed lateral ligament stabilisation	Rhys Thomas
Failed talar dome OCD debridement	Andy Goldberg

**Session 6****ANKLE FRACTURE**

Failed syndesmosis repair	Senthil Kumar
Malunion ankle fracture incl short fibula	Hiro Tanaka
Failed deltoid ligament repair	Sunil Dhar

**Session 7****ANKLE REPLACEMENT**

TAR malleolar fracture	Tim Clough
TAR malalignment/ loosening	Bob Sharp
TAR wound & neurovascular complications	Mike Karski

**Session 8****HINDFOOT & MIDFOOT SURGERY**

Malunion triple/midfoot arthrodesis	Nick Cullen
Non-union hindfoot/midfoot arthrodesis	Ioan Tudur Jones
Malunion calcaneal fracture	Ian Sharpe
Malunion/ Non-union talar neck fracture	Kurt Haendlmayer
AVN talar neck fracture	Steve Parsons
Navicular stress fracture	Nick Talbot

## Deep Vein Thrombosis

Debate continues on the perceived incidence of deep vein thrombosis (DVT) after foot and ankle surgery and the role of prophylaxis. This is partly because there is a discrepancy in the literature in the definition of what constitutes a deep vein thrombosis: symptomatic/ asymptomatic and particularly the distinction between distal (below knee or calf) or proximal (above knee or thigh) DVTs.

Calf DVTs are only detected if a whole leg ultrasound scan is performed. On the other hand many radiology departments follow the NICE Clinical Guideline 144 of 2012 to only scan and report on proximal DVTs, because whole leg ultrasound is time consuming and technically demanding. Calf DVTs only very rarely cause pulmonary emboli and are therefore not usually treated by anticoagulation. However about 30% of calf DVTs can propagate to become proximal DVTs in about a week and the NICE guidelines 144 state that proximal leg ultrasound should be repeated in 6-8 days in high risk patients (all orthopaedic patients). An audit at the Royal National Orthopaedic Hospital has shown that junior doctors are unaware of this guideline and requests for a repeat ultrasound scan are rarely made. DVTs after orthopaedic surgery may therefore be under-diagnosed and under-reported.

Patel et al. retrospectively reviewed a large U.S healthcare management database and identified 1172 patients with Achilles tendon ruptures and found a reported incidence of 0.43% of symptomatic DVTs. Scandinavian studies where a detailed sonographic study of the whole leg patients with an Achilles tendon rupture has been performed have stated that the incidence of symptomatic and asymptomatic DVT to be about 32%. Some clinicians thus perceive the incidence of DVT after Achilles tendon rupture to be high. A detailed study of the paper of Nilsson-Helander et al, for example, however identifies that of the 32 reported DVTs in 100 patients with symptomatic and asymptomatic DVTs, 27 were calf DVTs and 5 were thigh DVTs (the reported rate in the UK would thus be 5% and not the reported 32% rate in the study). It is thus suggested that all studies and guidelines on prophylaxis should clearly state whether calf DVTs are being considered.

### Prophylaxis

The NICE guidelines 2010 (section 2.2.6) on lower limb casts that highlights that patients in a cast should be risk assessed and LMWH discussed and offered. In 2012 we reached an unusual but satisfying 100% consensus that every patient should undergo risk assessment for DVT during elective surgery. Immobilisation and NWB status were highlighted as a significant risk factor.

**Current practice 2014:** The use of LMWH prophylaxis when in a NWB cast:

70% use prophylaxis after a triple fusion

80% use prophylaxis with Achilles tendon ruptures

100% use prophylaxis after ankle fracture if there is an additional risk factor

When in a WB cast...

15% would use prophylaxis in ankle fractures with no additional risk factors

## **Investigation**

Whilst the symptoms and signs of a DVT are often non-specific, it is the presence of symptoms/ signs or a high level of suspicion that alerts the clinician to investigate. Whilst venography may remain the gold standard, USS remains the most practical and widely available. D-dimer is of questionable use in the post-operative period as it will usually be raised.

### **Current practice 2014:** How to investigate if clinically suspicious for DVT

15% would measure the D-dimer

75% would refer for an USS (50% via hospital protocol)

65% would ask for USS whole leg

80% of those who refer for USS would repeat USS if negative but suspicion remained

However 0% used the Wells 2 level score as per the NICE guidelines

The NICE guidelines (figure) highlight that the Wells two level test probability score (figure) should be used to determine the probability of DVT and guide treatment.

## **Treatment of DVT**

### **Current practice 2014:** symptomatic proximal DVT

3 months anticoagulation if time limited risk factor i.e. cast/ immobilisation

6 months anticoagulation if risk factor isn't time limited

>12 months or lifetime anticoagulation if recurrent DVT or patient has a malignancy

### **Current practice 2014:** on distal DVT

30% would anticoagulate

10% would not anticoagulate

60% did not know and would consult DVT service/ haematologists

### **Consensus on DVT prevention 2014**

- All patients should be risk assessed for DVT
- Immobilisation in a NWB cast remains a significant risk factor and progressing patient to WB status, decreases this risk.
- Patients who are NWB in cast should have LMWH prophylaxis

### Consensus on the investigation of DVT

- The Wells two level score should be used to determine the probability of DVT with a referral for proximal leg USS within 4 hrs/ LMWH as appropriate.
- Proximal leg USS when negative in a high risk patient (e.g. postoperative) should be repeated at 6-8 days if clinical suspicion continues.
- The use of hospital protocols/ DVT service, where available, is recommended.

### References

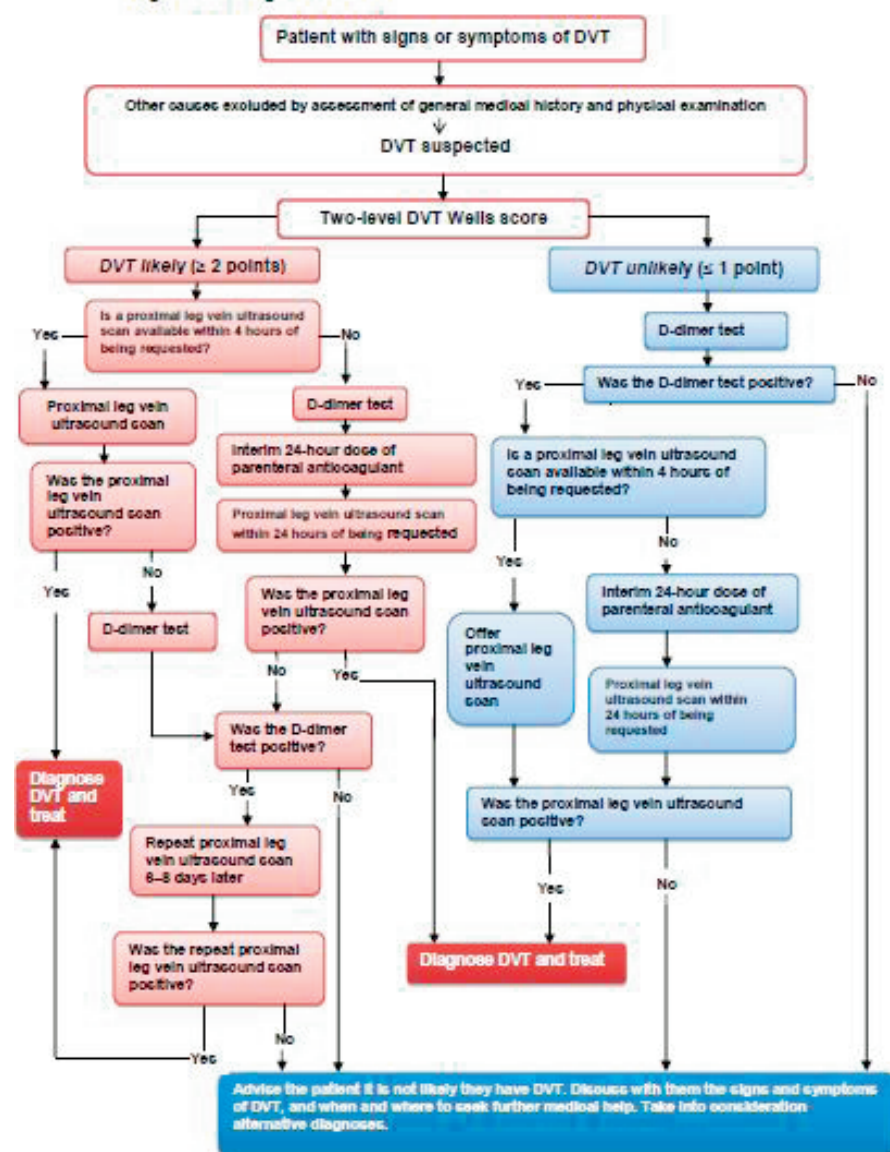
- 1 Venous thromboembolic diseases: the management of venous thromboembolic diseases and the role of thrombophilia testing. NICE Clinical Guidelines CG144. Issued June 2012.
- 2 Patel A, Ogawa B, Charlton T, Thordarson D. Incidence of deep vein thrombosis and pulmonary embolism after Achilles tendon rupture. Clin Orthop Relat Res 470:270-274,2012.
- 3 Nilsson-Helander K, Thurin A, Karlsson J, Eriksson BI. High incidence of deep vein thrombosis after Achilles tendon rupture: a prospective study. Knee Surg Sports Traumatol Arthrosc 2009.
- 4 Reducing the risk of venous thromboembolism (DVT & PE) in patients admitted to hospital. Clinical Guidelines CG92. Issued: January 2010.

### The Wells two level PE score

<b>Clinical feature</b>	<b>Points</b>
Clinical signs and symptoms of DVT (minimum of leg swelling and pain with palpation of the deep veins)	3
An alternative diagnosis is less likely than PE	3
Heart rate > 100 beats per minute	1.5
Immobilisation for more than 3 days or surgery in the previous 4 weeks	1.5
Previous DVT/PE	1.5
Haemoptysis	1
Malignancy (on treatment, treated in the last 6 months, or palliative)	1
<b>Clinical probability simplified score</b>	
PE likely	More than 4 points
PE unlikely	4 points or less

DVT diagnosis guidelines as suggested by NICE

**Algorithm 1 Diagnosis of DVT**



## Wound healing

There are times in all our practice when wound healing by primary intention is either not possible or unsuitable. The wound, whether surgical or traumatic, is then required to heal by secondary intention or via the transfer of tissue from elsewhere. The latter of these is almost exclusively under the control of the plastic surgeon which leaves us to deal with the slow to heal, often infected, granulating wound. It is in the management of such wounds that negative pressure wound therapy (NPWT) has gained popularity. The sceptics amongst us may say that this is due to slick marketing and “pseudoscience”, however in trying to reach consensus it was clear that in the management of a “difficult” wound their use is generally recommended.

**Current practice 2014:** Do you use Vac therapy for difficult to heal wounds?

- 100% yes

With such popularity it is useful to remind ourselves of what negative pressure dressing can add to wound management. They should not be used as a replacement for adequate wound irrigation and debridement or instead of a graft or flap by your local plastic surgeon. NPWT provides:

- Maintains a moist environment ✓
- Reduces oedema ✗
- Increases local blood flow ✓
- Stimulates angiogenesis and granulation tissue ✓
- Reduces wound size ✓
- Removes wound healing inhibitors ✗
- Reduces bacterial load ✗

**Consensus on the use of vac dressings.**

- Their use is generally recommended as an adjunct when primary wound closure or soft tissue transfer techniques are not appropriate.

## **Non-union – Diagnosis and management**

### **Diagnosis of Non-union**

Whilst we all accept that this diagnosis is based on a combination of symptoms, signs and imaging results, we often look towards the latter for an objective assessment of what can vary widely clinically.

**Current Practice 2014:** The use of CT to diagnose non-union

75% use CT for the diagnosis of a non-union

85% require 50% bony continuity for union on CT

However the percentage of bony continuity on CT does not have any clinical correlation and therefore whether the joint is fused or not fused ultimately depends on the clinical picture. Some groups would accept that given a lack of clinical symptoms bony continuity of 20-25% is sufficient to diagnose bony union.

### **How to address Non-union**

- Is it infected?
- Is there mechanical failure?
- Is the patient suitable for further surgery?
- Are there patient factors that can be managed better?

There are undoubtedly situations when there is infection and/ or mechanical failure of a fusion or fixation that will require early surgical intervention. However in the absence of either of these factors the use of adjuvant therapy is advocated. This may take the following forms:

- Bone stimulation: Implanted or external
- Concentrated growth factors
- BMP and alternatives

### **Bone stimulation**

A fracture site produces a negative electropotential. Through manipulation of this further cellular stimulation can be provided to promote bone healing. This can be provided internally or externally. There is a lot of evidence for long bones and its use is supported by NICE guideline MTG12. However, there is only early evidence to support its use in the ankle but not in the foot (1,2).

**Current practice 2014:** Use of Exogen stimulation

50% routinely use Exogen in non-unions

25% would like to use it but have funding issues

## **Growth Factor concentrate**

Bone marrow aspirate can be used independently or in combination with platelet rich plasma (PRP), injected into the site of concern and produce a small but measurable improvement in bone healing (3). Within this it is felt that BMA may play a greater role but there is to date insufficient evidence to support this.

## **BMP**

These are all members of the TGF- superfamily (except BMP-1). They are modulators of osteoprogenitor and mesenchymal cells during osseous healing. The genetically engineered rhBMP2/7 have limited approval and have to be used “off label” for foot and ankle cases. Despite this there is some limited evidence for their successful use in high risk ankle and hindfoot fusions such as diabetics, the immunosuppressed or following high energy injury(4).

## **Current practice 2014: Use of BMP for non-unions**

US surgeons use it for every case

20% of British surgeons use it routinely and have good access to it.

40% of British surgeons have to apply specially via commissioners

## **Hindfoot non-union experience from Guys Hospital**

Revision surgery for a hindfoot non-union should be performed in conjunction with your microbiologist. The experience from Guys Hospital follows the following steps:

1. Assume it is infected
2. No antibiotics until samples taken.
3. Give broad spec such as vancomycin and gent (dw micro)
4. Samples to take are 3xmicro and 3x histology
5. Send micro for PCR
6. If cultures are negative then antibiotics are discretionary and are only given if thought to be high risk
7. If cultures are positive then antibiotics are given as per sensitivities until union is achieved.

Infected non-unions are effectively therefore treated with a single stage revision and suppressive antibiotics until union. The pathogens noted from the experience at Guys are either staphylococcus aureus, enterobacter or pseudomonas.

## **Consensus**

- A non-union can be defined as a painful arthrodesis with <50% bony continuity
- Exogen stimulator use is recommended
- Bone stimulation with BMP/ growth factors for high risk patients
- Assume it is infected

### **Non-union – Risk factors**

Whilst the definition of a non-union remains variable, it is generally accepted that approximately 1 in 20 patients undergoing an elective ankle or hindfoot fusion will develop one. In the treatment or indeed the prevention of a non-union it is vital to identify the risk factors for poor bone healing. These risks can be broadly divided into host factors and surgical site factors.

The commonest host factors are infection, smoking, nutritional (vitamin D deficiency), diabetes, vascular compromise and systemic factors. The surgical site, the soft tissues and the mechanical environment the bone is placed under until it unites, is under our control.

#### **Infection:**

Staph Aureus has been shown to inhibit osteoblast activity and stimulates osteoclast activity (1). However infection can be sub-clinical with normal inflammatory markers and therefore difficult to detect. Culture results from problematic wounds can be misleadingly negative, in part due to biofilm formation and previous bacteriostatic antibiotic effects. Molecular diagnostics (DNA & RNA PCR) are more sensitive and thus play an important role in detecting infection as a cause of non-union.

#### **Smoking:**

The relative risk of developing a non-union as a smoker is up to 5X when compared to non-smokers. Also their time to union is 25% longer.

**Current practice 2014:** Would you perform an elective primary fusion on a smoker

40% would not

60% would advise to stop but operate anyway

#### **NSAIDs:**

There is some evidence in animal models that COX-2 inhibition inhibits early bone healing. However this hasn't been reproduced in humans (2).

Poor evidence in humans

**Current practice 2014:** Use of NSAIDs in a patient undergoing a fusion

50% advise against the use in the first 2 weeks

#### **Diabetics**

Whilst we all counsel a diabetic patient on the increased risks of surgery and also the time to union, there are three main factors that significantly increase bone healing complications (3):

1. Peripheral neuropathy
2. Duration of surgery
3. HbA1c >7%

To a great extent these risk factors can be controlled.

## Nutritional status

Vitamin D is essential for bone mineralisation and the subsequent maintenance of bone quality and fracture healing. Despite this the true benefits of supplementation even in vitamin D deficient patients remain unclear (4).

**Current practice 2014:** Do we investigate for vitamin d deficiency?

10% would test for it before primary surgery

25% would test for it in a patient with non-union

Currently in the USA the use of vitamin D supplementation, to promote bone healing/ union, in those undergoing major foot and ankle surgery is becoming widespread. Vit D level is not tested. This is based on a health-economics argument as the cost of vitamin D 5000 IU/day or 50,000 IU weekly for 3 weeks pre-operatively and 12 weeks post-operatively is significantly less (10%) than the laboratory test for deficiency.

## Consensus on non-union

- All patients with a non-union should undergo investigation for vitamin D deficiency. This can be performed and managed by the treating surgeon or a local metabolic bone specialist.
- Smokers should be advised of the increased risk of non-union and advised to stop and NSAIDs avoided in the 1<sup>st</sup> 2/52 post-op.
- Diabetic control needs to be optimum in the period leading up to their surgery and their HbA1c normalised in conjunction with a diabetologist. The surgical procedure on a diabetic need to be appropriately planned to minimise its duration.

## References

1. BMC musculoskeletal disorders. 2013 Jun 14;14:187
2. Kurmis. *J Bone Joint Surg Am*, 2012 May 02;94(9):815-823
3. *J Foot Ankle Surg*. 2013 Mar-Apr;52(2):207-11
4. *Bone*. 2014 Jul;64C:288-297
5. Midis N, Conti SF. Revision ankle arthrodesis. FAI 2002
6. Saltzman et al: PEMF as treatment for delayed healing of foot and ankle arthrodesis. FAI 2004
7. *Clin Orthop Rel Res*. DOI: 10.1007/11999-014-3548-3
8. Bibbo. *Tech Orthop* 2011;26: 28–31

## **Malunion**

A working definition of a malunion is when there is bony unity without proper restoration of the normal anatomical and weight-bearing axis of the limb. It can occur in multiple planes, which all need to be addressed.

- Angulation
- Translation/ displacement
- Shortening
- Rotation
- Complex

A malunion can occur due to a lack of adequate reduction at the time of surgery or due to insufficient construct stability. Stability needs to be maintained until the bone unites and requires the full compliance of the patient. The time taken for a bone to unite varies widely and risk factors such as smoking, nutritional deficiency, diabetes, vasculopathy and systemic disease such as rheumatoid should be taken into consideration.

Vitamin D deficiency was raised again as an area of renewed interest in such patients, especially from the USA.

**Current practice 2014:** Regarding the investigation for vitamin D deficiency

- 7% would test for in the presence of a symptomatic malunion

When there is a malunion it can have wide-ranging effects:

- Pain
- Dysfunction
- Instability
- Arthritis

When addressing a malunion deformity the principles of deformity adhered to. Deformity correction requires the identification of the mechanical and anatomical axis, the CORA (Centre of rotation and angulation) and the bisector line. The CORA is where the anatomical axis meet and the bisector line, a line that bisects the obtuse angle of that deformity at the CORA.

## **Consensus on malunion**

- Investigate for vitamin D deficiency
- Manage risk factors
- Follow Deformity correction rules
  - When osteotomy and hinge at level of CORA, only angulation is required to correct deformity
  - When osteotomy is done at a different level than the CORA, but hinge at level of CORA then angulation and translation are both required to correct deformity. The mechanical axis becomes parallel but anatomical axis becomes zigzag.
  - When osteotomy and hinge are both not at level of CORA then translation deformity occurs.
  - In complex deformities consider each CORA separately, or consider performing osteotomy at the resolved CORA to avoid multiple osteotomies.
- Obey the law of rhomboidal osteotomy. The apex of the wedge should be at the skin or beyond it. We are correcting bony and soft tissue deformity.

## Nerve injury

Neurological compromise can present with sensory, motor or mixed symptoms and signs, either as part of the primary pathology or as a complication of surgical management.

In the management of **post-operative** neurological compromise it is important to be able to rely on clinical symptoms and signs as investigation with MRI or even EMG is inconclusive and user dependant. Despite this both investigations should be used to exclude proximal lesions, accessory muscles, tumours and to highlight muscle function.

The common lesions around the foot and ankle are:

- Saphenous nerve
- Superficial peroneal nerve
- Deep peroneal nerve
- Tibial nerve
- Sural nerve

Damage to the deep peroneal or the tibial nerve would have major motor and sensory implications for the foot. Such lesions should generally be noticed within the acute phase and therefore be explored, repaired and/or decompressed.

The superficial sensory nerves or one of their aberrant branches may easily be damaged leaving a small area of insensate skin that is managed conservatively, but may subsequently develop a problematic superficial chronic neuroma.

Symptomatic chronic superficial nerve lesions should undergo exploration and decompression. In the presence of a neuroma, resection and burial in either bone, soft tissue or a nerve wrap should be performed.

### Consensus on treating nerve injury

- Rely on clinical symptoms and signs
- Acute lesions should be decompressed/repared
- Chronic lesion can be decompressed
- Neuromata:
  - Resect proximally
  - Resect deep to fascia
  - Burial in bone better than muscle
  - Keep away from the joint to avoid tension
  - Peri-operative use of local anaesthetic infiltration

## **Chronic Regional Pain Syndrome (CRPS)**

Patients in chronic pain often feel misunderstood and may exaggerate symptoms or signs in order to get clinicians to understand and acknowledge their problem. This makes this a difficult area of our practice to manage.

**CRPS can be seen in up to 25% (1, 2, 3) of post-operative/ post trauma patients but in some CRPS patients there is no obvious preceding cause (4). It is usually confined to a single limb but can “spread” to additional limbs in 7% (5-7).**

**It is often divided into 2 subtypes**

- **Type 1 – Absence of major nerve lesion**
- **Type 2 – Presence of major nerve lesion (more common)**

There are many reasons why a patient may have ongoing pain post-operatively including malunion, non-union, loose prosthesis, infection, nerve injury, metal allergy and psychosocial. It is therefore wise to take a broad approach to the investigation and management of such patients and only come to a conclusion of complex regional pain syndrome (CRPS) when other causes have been excluded.

In addition to excluding other causes of pain, CRPS has typical symptoms and signs that need to be observed before the diagnosis can be made. These are highlighted by the Budapest criteria (8).

### **Budapest criteria**

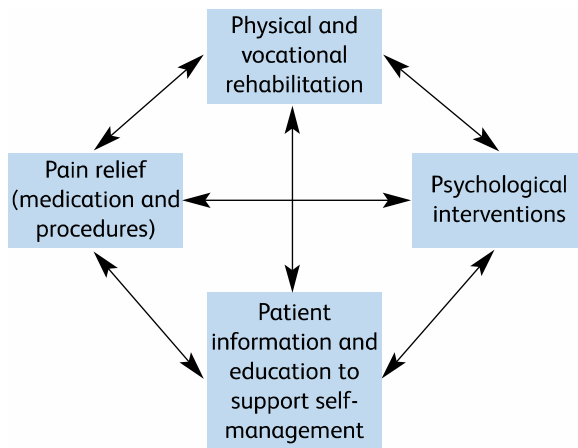
**To make a clinical diagnosis the following criteria must be met:**

1. **Continued pain, disproportionate to the inciting event**
2. **Must report at least one symptom in three of the following four categories**
  - i. **Sensory-Hypraesthesia and/or allodynia**
  - ii. **Vasomotor- temperature asymmetry and skin colour changes**
  - iii. **Pseudomotor/ oedema-sweating changes**
  - iv. **Motor/ trophic- stiffness, weakness, hair loss, nails, skin**
3. **Must display at least one sign in two or more of the following categories**
  - i. **Sensory-Evidence of hyperaesthesia and/or allodynia**
  - ii. **Vasomotor- Skin temperature asymmetry  $>1^{\circ}\text{C}$  and skin colour changes**
  - iii. **Pseudomotor/ Oedema-Evidence of sweating changes**
  - iv. **Motor/ trophic- Evidence of stiffness, weakness or trophic changes hair loss, nails, skin**
4. **No other clinical diagnosis that explains symptoms/ signs**

**The chronicity of symptoms may be predicted by the presence of psychosocial risk factors or “yellow flags”.**

- Previous negative experiences with health professionals
- Poor coping strategies
- Litigation
- Overuse of appliances
- Passivity
- Negative family influences
- **Distress**
- **Anxiety/ Depression**

**Once identified the prompt treatment of CRPS is vital, as this prevents the lack of use of the affected limb and the psychological effects of chronic pain. An integrated multidisciplinary approach including the four pillars of treatment is required and all but mild cases should be managed by the chronic pain service.**



**Current practice 2014:** Operating on a limb affected by CRPS

- 55% would want CRPS to settle first

The probability of recurrent symptom in a limb previously affected by CRPS is 1 in 8, although symptoms tend to be milder the second time around. There is some potential benefit in the removal of

metalwork in someone with CRPS as there may occasionally be an undiagnosed metal allergy contributing to the pain.

### **Consensus on re-operating on those with CRPS**

- Deal with ongoing underlying orthopaedic pathology
- Remove metalwork
- Pain team management of CRPS symptoms before and afterwards
- Consider vitamin C and pregabalin prophylaxis
- Amputation as an extremely last resort as only 25% successful

- 1) Atkins et al JBJS BR 1990
- 2) Dijkstra et al Eur J Pain 2003
- 3) Schasfoort et al Arch Phys Med Rehabil 2004
- 4) Baran et al. Anesth Anal 2002
- 5) Veldman et al. Lancet 1993
- 6) Van Rijn et al J Neural Trans 2011
- 7) Maleki et al. Pain 2000
- 8) Beerthuizen et al Eur J Pain 2009

## Recurrent Hallux Valgus

“Despite correct selection and application of surgical techniques, it is a fact that recurrence still occurs.”

Recurrent hallux valgus is a problematic topic, first because it is not always clearly defined in the literature. It is often surgeon defined and therefore prone to bias. One could use the hallux valgus angle (HVA), the inter-metatarsal angle (IMA) or the position of the sesamoids.

Faber<sup>1</sup>, comparing Hohmann distal closing wedge osteotomy with the Lapidus procedure, defined recurrence as an AOFAS score of 0 for alignment and/or those who were dissatisfied.

Austin and Leventen<sup>2</sup> using the Chevron osteotomy quoted a recurrence rate of 10%. Okuda<sup>3</sup> had around 10% recurrence after basal osteotomies. The initial pathology, severity of valgus, the ability to apply general principles and finally the execution of the surgery are probably more important than the particular osteotomy used.

Minimally invasive surgery has a wide range of quoted recurrence rates, from 2.6% to 40%, which makes interpretation of this literature difficult without further work.

Patients may have recurrence of painless deformity, but remain satisfied, or *vice versa*. Faber found that 50% of those with recurrence were satisfied, would have the surgery again and did not want revision surgery. Equally, not all patients with a good correction will have a good outcome score.

Sammarco<sup>4</sup> found that risk factors for recurrence include:

- rheumatoid arthritis
- generalised or localised hypermobility
- a neurological aetiology
- osteoarthritis
- Poor compliance with post-operative instructions.

Okuda found the pre-operative HVA was predictive.

### Management of recurrence

**Conservative measures**, including adapted shoes, should not be dismissed. The technical and psychological challenge of revision surgery for patient and surgeon should point both towards this option.

If the initial correction was inadequate, a **reliable, powerful osteotomy** may be a reasonable and uncomplicated option – such as the Scarf<sup>5</sup> – combined as always with balanced soft tissue reconstruction. Kitaoka and Patzer<sup>6</sup> used a crescentic basal osteotomy on 16 feet, giving moderate results (10 satisfied, 2 dissatisfied).

Hypermobility of the first ray (often defined as 1cm of dorso-plantar movement relative to the second ray) may be relevant to recurrence, but is controversial. There is debate as to whether it is causative or secondary in hallux valgus, and whether it stabilises after correction. Nevertheless the concept, that

hypermobility allows an osteotomised metatarsal to escape into varus again, seems plausible. This leads naturally to the proposal of the **Lapidus procedure (corrective 1<sup>st</sup> TMT arthrodesis)**. Coetzee et al<sup>7</sup> used it as salvage for failed hallux valgus surgery in 26 feet, with good improvement in angles and no recurrence, but with three non-unions and only 77% unreserved satisfaction (one patient dissatisfied). Bednarz and Manoli's series<sup>8</sup> of primary Lapidus procedures for hypermobile feet showed almost a 20% recurrence rate, but with 96% satisfaction, and a Okuda et al's randomised controlled trial<sup>3</sup> of Lapidus procedure vs Hohmann osteotomy for unselected feet with hallux valgus, found a 9% recurrence rate and a 20% dissatisfaction rate with the Lapidus procedure at 10 years. The trial also showed no difference between the recurrence rates for the two contrasting procedures, even in a subgroup of patients with pre-operative first ray hypermobility. The procedure also has a long recovery with most surgeons advising several weeks spent non weight bearing in a cast, and, being proximal, it is both powerful and technically demanding, and so is unappealing to many surgeons.

**First metatarso-phalangeal arthrodesis** may seem an attractive option, offering as it does the chance to virtually rule out a second recurrence, but it does remove a significant function in eliminating 1<sup>st</sup> MTP movement. Grimes and Coughlin<sup>9</sup> published a series of 33 patients, 55% of whom were treated for recurrent deformity, and delivered 88% patient satisfaction with correction, but an overall satisfaction rate of 72% "good or excellent". First MTP fusion may risk later inter-phalangeal joint arthritis. It does however offer early weight bearing and is surely the procedure of choice in an arthritic, valgus joint.

In summary, no procedure has universal success after failed hallux valgus surgery and conservative management should be discussed and offered. Osteotomies, 1<sup>st</sup> TMT fusion or 1<sup>st</sup> MTP fusion can all be justified, but more importantly, the factors leading to failure should be analysed and then addressed during the revision. The surgeon should counsel patients that around 20% may still be dissatisfied after revision surgery and that fusions have a significant non-union rate.

## Discussion

In response to questions on technique for the Lapidus procedure, Dr Coetzee clarified that when the first ray is hypermobile, he believes the first and second metatarsals should be prepared for fusion and joined proximally with a screw to achieve true stability. He finds this technique provides a solid fusion and satisfaction, without screw breakage or complaints about a non-mobile first ray.

## References

1. Faber FW, van Kampen PM, Bloembergen MW. Long-term results of the Hohmann and Lapidus procedure for the correction of hallux valgus: a prospective, randomised trial with eight- to 11-year follow-up involving 101 feet. *Bone Joint J.* 2013;95-B:1222-1226.
2. Austin DW, Leventen EO. A new osteotomy for hallux valgus: a horizontally directed "V" displacement osteotomy of the metatarsal head for hallux valgus and primus varus. *Clin Orthop Relat Res.* 1981;25-30.
3. Okuda R, Kinoshita M, Yasuda T, Jotoku T, Shima H. Proximal metatarsal osteotomy for hallux valgus: comparison of outcome for moderate and severe deformities. *Foot Ankle Int.* 2008;29:664-670.

4. Sammarco GJ, Idusuyi OB. Complications after surgery of the hallux. *Clin Orthop Relat Res.* 2001;59-71.
5. Bock P, Lanz U, Kroner A, Grabmeier G, Engel A. The Scarf osteotomy: a salvage procedure for recurrent hallux valgus in selected cases. *Clin Orthop Relat Res.* 2010;468:2177-2187.
6. Kitaoka HB, Patzer GL. Salvage treatment of failed hallux valgus operations with proximal first metatarsal osteotomy and distal soft-tissue reconstruction. *Foot Ankle Int.* 1998;19:127-131.
7. Coetzee JC, Resig SG, Kuskowski M, Saleh KJ. The Lapidus procedure as salvage after failed surgical treatment of hallux valgus: a prospective cohort study. *J Bone Joint Surg Am.* 2003;85-A:60-65.
8. Bednarz PA, Manoli A. Modified Lapidus procedure for the treatment of hypermobile hallux valgus. *Foot Ankle Int.* 2000;21:816-821.
9. Grimes JS, Coughlin MJ. First metatarso-phalangeal joint arthrodesis as a treatment for failed hallux valgus surgery. *Foot Ankle Int.* 2006;27:887-893.

## Hallux Varus

The most common cause of hallux varus is iatrogenic, after hallux valgus surgery. Less common causes include congenital, traumatic, burns contracture, inflammatory arthritis and neuromuscular.

Rates of post-operative hallux varus in the literature range from 4% (Choi, Brodsky et al<sup>1</sup>) to 17% (Trnka et al<sup>2</sup>). Part of the disparity is explained by the inclusion of asymptomatic cases in Trnka's series, whereas Choi only counted those who returned spontaneously and were dissatisfied. Trnka used a powerful basal metatarsal osteotomy, which may also have contributed.

### Causes of iatrogenic hallux varus

Any of the steps of hallux valgus surgery can cause varus if exaggerated.

**Excessive resection of the medial eminence** removes the bony support for the medial side of the proximal phalanx and was felt to be the leading cause of varus in Trnka's series.

**Over-correction of the intermetatarsal angle (IMA) or of the valgus interphalangeus** are also obvious causes and predominated in Choi's series.

**Excessive lateral release** (dividing the lateral collateral ligament, for instance), over-tightening of the medial capsulorrhaphy (common in the McBride procedure) and aggressive post-operative bandaging may result in varus through soft tissue imbalance.

**Excision of the fibular sesamoid** is another known iatrogenic cause of varus.

As varus progresses it may be accompanied by clawing of the hallux (especially if FHB was released), an in-growing toenail and adduction of the lesser toes.

Trnka found that two thirds of patients tolerated varus well with "excellent" subjective outcomes. It was poorly tolerated if the angle was over 15 degrees, if there was transfer metatarsalgia or osteoarthritis of the MTP joint.

### Management

Conservative management of hallux varus ranges from leaving it alone, splinting in the early phase to encourage lateral soft tissues to contract, to adapting shoes with a wide, deep toe box later on.

Operative management in the presence of arthritis should be with first MTP fusion.

If there is a fixed claw hallux, interphalangeal fusion should be combined with MTP realignment procedures.

Osseous corrections essentially reverse the steps in hallux valgus correction, and include bone grafting the medial eminence as required; first metatarsal osteotomy; and "reverse Akin" osteotomy of the proximal phalanx.

Rochwerger<sup>3</sup> reviewed 7 out of 8 patients who had undergone bone grafting of the medial eminence with iliac crest graft and showed good corrections into 16-22 degrees of valgus. Only the patient with 22 degrees was dissatisfied.

Scarf or Chevron osteotomies can be used to reverse hallux varus by medialising the head and correcting the distal metatarsal articular angle as necessary. Brodsky<sup>1</sup> treated thirteen patients with scarf/Akin and six with Chevron/Akin osteotomies. One patient was dissatisfied and two had recurrent varus. He noted that a pre-operative limited range of motion often improved after the correction.

Many soft tissue corrections have been devised which involve tendon transfers. Essentially they aim to reconstruct a deficient lateral collateral ligament and adductor tendon. Johnson's dynamic extensor hallucis longus (EHL) transfer<sup>4</sup> takes the tendon from the distal phalanx, threads it under the intermetatarsal ligament and transfers it into the lateral side of the proximal phalanx, fusing the interphalangeal joint to prevent clawing.

Myerson's modification<sup>5</sup> splits EHL, leaving both halves attached distally, and threads the proximal end under the intermetatarsal ligament and into the first metatarsal as a static stabiliser. Another variant uses EHB<sup>6</sup>.

Valtin described a transfer of the first dorsal interosseous muscle from the second toe into the first<sup>7</sup>. Hawkins takes the distal attachment of abductor hallucis, passes it under the metatarsal and into the lateral aspect of the proximal phalanx<sup>7</sup>. A "reverse Hawkins" procedure divides the abductor proximally and transfers this end under the phalanx and into the lateral aspect of the first metatarsal. An analogous procedure has been described in one case using a mini-tightrope implant.

Plovanich et al<sup>7</sup> reviewed eight studies reporting a total of 68 feet. With a mean follow up of 30 months, there were 80-85% "good" results and 16% complication rate. These included four cases of osteoarthritis, three of recurrent varus, and two of hallux valgus.

In conclusion, iatrogenic hallux varus is best avoided by judicious hallux valgus surgery, but mild varus is well tolerated. Appropriate bony correction gives reliable results. There are several possible tendon transfers but little evidence to choose between them.

## **Discussion and Consensus**

Of the 34 surgeons present, 30/34 (88%) had had at least one post-operative hallux varus. The majority had been treated with bony procedures. Thirteen surgeons had treated one or more patients with a soft tissue only procedure alone. The consensus was that surgeons would do this if no bony correction was required.

It was suggested that recurrence and varus are two sides of the same coin, that is under and over correction. Incorrect selection of technique may contribute, e.g. using a proximal osteotomy to correct a mild hallux valgus is quite likely to over-correct.

The issue of whether to use intra-operative fluoroscopy was raised. Fourteen of 34 (41%) never use it, eight (24%) always use it and eight sometimes use it e.g. for difficult cases. Mr Molloy presented 31 cases performed without fluoroscopy, compared with 31 cases done with fluoroscopic guidance after a change in practice<sup>8</sup>. Although not randomised, this study showed a statistical difference in the amount of correction (bigger correction achieved when using fluoroscopy) and better positioning of the sesamoids on post-operative radiographs, and for this reason he recommends it. Others urged

colleagues to adopt intra-operative fluoroscopy both to protect themselves medicolegally and to encourage best practice throughout the profession, but there was considerable opposition to this, not least because fluoroscopy availability is limited.

Fourteen (41%) surgeons requested post-operative check radiographs within a day of surgery (if not taken intra-operatively), whereas eleven (32%) did not request radiographs until six weeks post-operatively.

## References

1. Choi JH, Zide JR, Coleman SC, Brodsky JW. Prospective study of the treatment of adult primary hallux valgus with scarf osteotomy and soft tissue realignment. *Foot Ankle Int.* 2013;34:684-690.
2. Trnka HJ, Zettl R, Hungerford M, Muhlbauer M, Ritschl P. Acquired hallux varus and clinical tolerability. *Foot Ankle Int.* 1997;18:593-597.
3. Rochwerger A, Curvale G, Groulier P. Application of bone graft to the medial side of the first metatarsal head in the treatment of hallux varus. *J Bone Joint Surg Am.* 1999;81:1730-1735.
4. Johnson KA, Spiegel PV. Extensor hallucis longus transfer for hallux varus deformity. *J Bone Joint Surg Am.* 1984;66:681-686.
5. Skalley TC, Myerson MS. The operative treatment of acquired hallux varus. *Clin Orthop Relat Res.* 1994;183-191.
6. Myerson MS, Komenda GA. Results of hallux varus correction using an extensor hallucis brevis tenodesis. *Foot Ankle Int.* 1996;17:21-27.
7. Plovanich EJ, Donnenwerth MP, Abicht BP, Borkosky SL, Jacobs PM, Roukis TS. Failure after soft-tissue release with tendon transfer for flexible iatrogenic hallux varus: a systematic review. *J Foot Ankle Surg.* 2012;51:195-197.
8. Holland P, Molloy AP. Intra-operative radiography for scarf osteotomies of the first metatarsal. *Bone Joint J.* 2013;95-B:21.

## Transfer Metatarsalgia after Hallux Valgus Surgery

Transfer metatarsalgia can be defined as forefoot pain caused by dysfunction in another forefoot area<sup>1</sup>. It occurred not uncommonly after older first metatarsal osteotomies like the Wilson and the Mitchell osteotomies, with rates quoted at 11-20%<sup>2-4</sup>. It is commoner in the Greek foot type. Incidence with modern surgery is unknown.

Virtually all first metatarsal osteotomies cause some shortening and may also inadvertently elevate the first metatarsal head. This prevents normal loading of the first ray during the second and third rockers of gait, transferring more load to the lesser metatarsal heads. "Too much" shortening has been defined<sup>5</sup> as 4mm or a ratio<sup>6</sup> of lengths of first and second metatarsal of less than 0.825.

When the load transfer is minimal the patient can adapt her gait and activities, but when severe, it tends to progress, with callus formation and plantar plate rupture, and may co-exist with recurrent hallux valgus or first MTP arthrosis. In this situation the normal forefoot mechanics need to be restored.

Careful examination can detect these signs as well as an elevated or short first metatarsal, and can distinguish between second rocker metatarsalgia, with callus directly under the metatarsal heads, and third, where the callus is more distal. These indicate that the problem is elevation or shortening of the first metatarsal, respectively. More patients experience pain in the third than in the second rocker – perhaps because, in third rocker, the load is not shared with any other part of the foot. The position of the sesamoids may also have a role in proper loading of the first metatarsal.

Gastrocnemius tightness has been implicated by many researchers in metatarsalgia<sup>7,8</sup> and should be included in the assessment.

Radiological assessment starts with weight bearing DP and lateral radiographs and an oblique. The state of the joints is assessed, previous surgery noted and particular attention paid to the degree of shortening and elevation of the first metatarsal. Computed tomography, particularly weight bearing if available, shows the relative height of different metatarsals very precisely. If this is not available a skyline view of the forefoot is occasionally a very useful tool [*scribe's addition*].

Within the umbrella of non-operative management, padding around the prominent metatarsals has good evidence, and adding a rocker to the shoe can offload the forefoot<sup>9</sup>. Stretching the gastrocnemius-soleus complex to reduce the relative pressure through the forefoot also has good evidence<sup>10</sup>.

Although load transfer to the forefoot is very complex when looked at with finite element analysis, surgical treatment aims to restore particularly the first metatarsal's role in taking more than one third of the body weight during stance phase. Maestro proposed his metatarsal parabola<sup>11</sup>, a description of the ideal relative lengths of the metatarsals, which, although not a perfect model, is as good a guide as any in terms of length, as long as relative elevation or depression of the metatarsal heads is also considered.

Lengthening of the first ray can be achieved with an osteotomy if for recurrent hallux valgus, or with bone block arthrodesis for first MTP arthrosis. For pure elevation, Caminear<sup>12</sup> described an opening wedge plantar flexion osteotomy of the first ray. First MTP Replacement is a controversial way to achieve lengthening and probably not to be recommended in a complex revision situation. Alternatively the ideal metatarsal parabola can be achieved by shortening one or more lesser rays with osteotomies as described by Weil, Helal, Maceira or percutaneous distal metatarsal minimally

invasive osteotomy (DMMO) but each have their problems with stiff or floating toes, transfer pain to other rays, and delayed union (see later section on lesser metatarsals).

While post-operative metatarsalgia is usually a biomechanical problem requiring surgical correction, other causes of post-operative metatarsalgia should always be considered including non-union, infection, nerve injury, CRPS, hallux varus, and avascular necrosis of the first metatarsal head. Before embarking on complex surgery to correct the biomechanics, non-surgical exacerbating factors should be considered - over-training in the athlete, excessive weight, poor shoe choice and forefoot fat atrophy – and caution should be taken in counselling these patients for surgery.

## References

1. Illustrated Dictionary of Podiatry and Foot Science. Elsevier Limited; 2009
2. Mitchell CL, Fleming JL, Allen R, Glenney C, Sanford GA. Osteotomy-bunionectomy for hallux valgus. *J Bone Joint Surg Am.* 1958;40-A:41-58; discussion 59.
3. Wilson JN. Oblique Displacement Osteotomy For Hallux Valgus. *J Bone Joint Surg Br.* 1963;45:552-556.
4. Merkel KD, Katoh Y, Johnson EWJ, Chao EY. Mitchell osteotomy for hallux valgus: long-term follow-up and gait analysis. *Foot Ankle.* 1983;3:189-196.
5. Carr CR, Boyd BM. Correctional osteotomy for metatarsus primus varus and hallux valgus. *J Bone Joint Surg Am.* 1968;50:1353-1367.
6. Schemitsch E, Horne G. Wilson's osteotomy for the treatment of hallux valgus. *Clin Orthop Relat Res.* 1989;221-225.
7. Barouk P. Recurrent metatarsalgia. *Foot Ankle Clin.* 2014;19:407-424.
8. Aronow MS, Diaz-Doran V, Sullivan RJ, Adams DJ. The effect of triceps surae contracture force on plantar foot pressure distribution. *Foot Ankle Int.* 2006;27:43-52.
9. Chang AH, Abu-Faraj ZU, Harris GF, Nery J, Shereff MJ. Multistep measurement of plantar pressure alterations using metatarsal pads. *Foot Ankle Int.* 1994;15:654-660.
10. Gajdosik RL, Vander Linden DW, McNair PJ et al. Viscoelastic properties of short calf muscle-tendon units of older women: effects of slow and fast passive dorsiflexion stretches in vivo. *Eur J Appl Physiol.* 2005;95:131-139.
11. Maestro M, Besse JL, Ragusa M, Berthonnaud E. Forefoot morphotype study and planning method for forefoot osteotomy. *Foot Ankle Clin.* 2003;8:695-710.
12. Caminear DS. Role of metatarsus primus elevatus in the pathogenesis of hallux rigidus.[letter]. *Foot Ankle Int* 2000;21(11):967.

## Avascular Necrosis of the First Metatarsal Head

Avascular necrosis (AVN) of the first metatarsal is almost always iatrogenic, caused through a disruption of the blood supply.

Sarraffian<sup>1</sup> in 1993 described seven variations in the way the dorsalis pedis artery gives rise to the artery of the first web space. It may pass dorsal to the intrinsic muscles, plantar to them or through them, for instance. Other authors (including Sherreff<sup>2</sup>, Resch<sup>3</sup>, Barouk<sup>4</sup>, Edwards<sup>5</sup>) have contributed since and the consensus in the literature is that the head is supplied mainly by plantar metaphyseal branches from the medial plantar artery and also by somewhat less important dorsal branches, as well as the nutrient artery of the first metatarsal, which is derived from the dorsalis pedis. The nutrient artery is inevitably separated from the head in any osteotomy, leaving the plantar vessels as the main blood supply to be respected during the surgical approach. Kumar<sup>6</sup> found that specifically the plantar-lateral corner of the metatarsal neck is the predominant site for vascular ingress. Barouk has emphasised the importance of the plantar metaphyseal artery.

AVN has occasionally been associated with steroid injections and open cheilectomies, but most notably with distal metatarsal osteotomies. It has been noted in Silver's, Mitchell's, Wilson's and the Chevron osteotomy<sup>7-12</sup>, with rates of around 20% common historically. Some of these authors raised the possibility that it was the combination of a lateral release (damaging the plantar-lateral vessels) with an osteotomy that caused AVN. Kuhn et al<sup>13</sup> used a laser Doppler probe intra-operatively, and showed that either lateral release or Chevron osteotomy *alone* reduced the flow only minimally, but together they reduced it by over 70%. These authors and several others since, however, reported an absence of AVN during follow up, including Resch<sup>3</sup>, who randomised patients to a Chevron with or without a lateral release. Edwards<sup>5</sup> recommended that the osteotomy should exit extra-capsularly and should have a longer plantar limb, in order to preserve the afore-mentioned plantar metaphyseal vessels.

The radiographic diagnosis of AVN can be challenging, given the presence of the sesamoids, post-surgical changes and sometimes incidental degenerative cysts. It also requires serial post-operative radiographs – a practice which incurs cost and which is therefore implicitly discouraged in some modern healthcare systems. Initial porosity gives way to sclerosis, then fragmentation and a crescent sign (subchondral fracture), and finally signs of osteoarthritis.

Meier and Kenzora<sup>8</sup> classified AVN radiographically as:

Stage 1 : pre collapse

Stage 2 : collapse

Stage 3 : arthritis

Further imaging may include bone scintigraphy, which has high sensitivity but can be difficult to interpret soon after surgery and so has low specificity; computed tomography to tell of the extent of bone death; and MRI, which again is sensitive but cannot necessarily differentiate AVN from oedema, fracture, infection, CRPS or even a Charcot process.

If non-operative management with off-loading and so on fails, the surgical options are arthrodesis, replacement or a Keller excision arthroplasty. Arthrodesis effectively treats joint pain and arthrosis, and has good results reported<sup>7,14</sup>. It is biologically plausible that it also enables re-vascularisation via

the fused phalanx. By contrast, there is no strong case in the literature for replacement after AVN, while a Keller's may be an option for a low demand patient.

Thankfully, in modern UK practice where long limb Chevron and scarf osteotomies predominate, AVN is rare, but surgeons should keep the diagnosis in mind when reviewing a dissatisfied post-operative patient.

## References

1. Sarrafian SK. Anatomy of the Foot and Ankle: descriptive, topographic, functional. Lippincott Williams & Wilkins, 1993, pp.375-425.
2. Shereff MJ, Yang QM, Kummer FJ. Extraosseous and intraosseous arterial supply to the first metatarsal and metatarsophalangeal joint. *Foot & Ankle Int.* 1987;8(2):81-93.
3. Resch S, Stenstrom A, Gustafson T. Circulatory disturbance of the first metatarsal head after Chevron osteotomy as shown by bone scintigraphy. *Foot Ankle.* 1992;13:137-142.
4. Barouk LS. Scarf osteotomy for hallux valgus correction. Local anatomy, surgical technique, and combination with other forefoot procedures. *Foot Ankle Clin.* 2000;5:525-558.
5. Edwards WH. Avascular necrosis of the first metatarsal head. *Foot Ankle Clin.* 2005;10:117-127.
6. Malal JGG, Shaw-Dunn J, Kumar CS. Blood supply to the first metatarsal head and vessels at risk with a chevron osteotomy. *JBJS (Am).* 2007;89:2018-2022.
7. Brodsky JW, Ptaszek AJ, Morris SG. Salvage first MTP arthrodesis utilizing ICBG: clinical evaluation and outcome. *Foot Ankle Int.* 2000;21:290-296.
8. Meier PJ, Kenzora JE. The risks and benefits of distal first metatarsal osteotomies. *Foot Ankle.* 1985;6:7-17.
9. Courtman NH, Weighill FJ. Distal first metatarsal osteotomy and adductor release as a treatment of hallux valgus. *J R Coll Surg Edinb.* 1995;40:133-135.
10. Peterson DA, Zilberfarb JL, Greene MA, Colgrove RC. Avascular necrosis of the first metatarsal head: incidence in distal osteotomy combined with lateral soft tissue release. *Foot Ankle Int.* 1994;15:59-63.
11. Thomas RL, Espinosa FJ, Richardson EG. Radiographic changes in the first metatarsal head after distal chevron osteotomy combined with lateral release through a plantar approach. *Foot Ankle Int.* 1994;15:285-292.
12. Johnston K, Cracchiolo A. The effect of chevron osteotomy with lateral capsular release on the blood supply to the first metatarsal head. *JBJS (Am)* 1995;77-A:2:197
13. Kuhn MA, Lippert FG, Phipps MJ, Williams C. Blood flow to the metatarsal head after chevron bunionectomy. *Foot Ankle Int.* 2005;26:526-529.
14. Brosky TA, Menke CR, Xenos D. Reconstruction of the first metatarsophalangeal joint following post-cheilectomy avascular necrosis of the first metatarsal head: a case report. *J Foot Ankle Surg.* 2009;48:61-69.

## Failed Cheilectomy

Cheilectomy for hallux rigidus can be said to have failed if pain persists and/or dorsiflexion remains limited. In the speaker's experience most failures are avoidable by careful patient selection. In a systematic review, failure occurred in just under 10% of cheilectomies<sup>1</sup>, and most of these were revised to first MTP fusion. However, before automatically offering fusion, surgeons should consider causes of failure other than painful arthrosis.

In selecting patients for cheilectomy, surgeons should perform the “grind test” (axial compression combined with a twisting motion) and an impingement test, with the foot loaded, the first metatarsal held down and the toe dorsiflexed up to end range. These tests are equally useful in a patient with a failed cheilectomy. Clinical examination may indeed point to painful arthrosis as the cause, but may also detect ongoing impingement, suggesting inadequate cheilectomy; or signs of infection, nerve injury or complex regional pain syndrome.

Depending on the cause, the surgeon may suggest footwear modification (a more roomy toebox, a forefoot rocker in the sole) and the patient may or may not accept it. A steroid injection may soothe residual synovitis, which may be indicated by a soft block to dorsiflexion on impingement testing. Revision cheilectomy may be warranted if pain returns after injection, the grind test is negative, and most of the joint is preserved on radiographs. The speaker performs minimally invasive revision cheilectomy with a low speed burr, accompanied by an arthroscopy of the joint which allows inspection and treatment of the joint surfaces. Some would advocate adding a dorsiflexion osteotomy (e.g. BonneyMcNab also called Moberg osteotomy) of the proximal phalanx, particularly if intra-operative dorsiflexion is still less than 70 degrees after the cheilectomy<sup>2,3</sup>.

For continuing painful arthrosis, fusion would probably be regarded as the “gold standard”, but alternatives are a Keller arthroplasty, joint replacement or interposition arthroplasty. Joint replacements are attractive to patients and surgeons alike but, when they fail they leave a large bone defect which is a considerable reconstructive challenge. Nevertheless one may consider hemiarthroplasty with a metal component which appears to be robust for several years<sup>4</sup>. In the older patient (eg over 60) the more familiar silastic replacement gives good results in most<sup>5</sup>. The Keller procedure (partial excision of the proximal phalanx) was ubiquitous a generation ago but is rarely done now. It may still be performed for hallux rigidus, with good results reported<sup>6</sup>. It has the advantage that there is no metalwork that can fail, loosen or get infected, and no bony union or osseous integration is expected, so it may be suited to a low demand patient who cannot tolerate the recovery period after arthrodesis or joint replacement. Interpositional arthroplasty is a variant of the Keller procedure and also has been reported<sup>7</sup>.

In summary, where cheilectomy is deemed to have failed, the surgeon should take a few minutes to consider the possible reasons and to address them in treatment, although in practice, a fusion will usually be the revision procedure of choice.

## Discussion

The discussion centred on patient selection for cheilectomy, which many felt was the primary influence on the success rate of the procedure. Mr Bendall reiterated that the decision to do a

cheilectomy is best made on clinical grounds rather than on radiographs. He would guide a patient with no joint space towards a fusion, but would leave the choice of cheilectomy open to them if impingement were the dominant problem. On the other hand, Mr Robinson pointed out that patient choice does not guarantee patient satisfaction.

While a minority of those present would add a dorsiflexion osteotomy, Mr Stephens pointed out that the patient most likely to benefit is the sportsperson who relies on the third rocker. Mr Williamson decompresses the first MTP joint with a shortening Chevron first metatarsal osteotomy, and finds this helps restore a useful range of movement.

### **Consensus**

66% of those present offer a simple, open cheilectomy on a suitable patient.

18% offer minimally invasive cheilectomy.

9% sometimes add a Moberg or Akin osteotomy.

3% sometimes add a first metatarsal osteotomy.

3% do not offer cheilectomy.

None of those present routinely add an osteotomy to a cheilectomy.

### **References**

1. Roukis TS. The need for surgical revision after isolated cheilectomy for hallux rigidus: a systematic review. *The Journal of Foot and Ankle Surgery*. 2010;49:465-470.
2. Citron N, Neil M. Dorsal wedge osteotomy of the proximal phalanx for hallux rigidus. Long-term results. *Journal of Bone & Joint Surgery, British Volume*. 1987;69:835-837.
3. Waizy H, Czardybon MA, Stukenborg-Colsman C et al. Mid-and long-term results of the joint preserving therapy of hallux rigidus. *Archives of orthopaedic and trauma surgery*. 2010;130:165-170.
4. Townley CO, Taranow WS. A metallic hemiarthroplasty resurfacing prosthesis for the hallux metatarsophalangeal joint. *Foot & Ankle International*. 1994;15:575-580.
5. Laird L. Silastic joint arthroplasty of the great toe: a review of 228 implants using the double-stemmed implant. *Clinical orthopaedics and related research*. 1990;255:268-272.
6. Schneider W, Kadnar G, Kranzl A, Knahr K. Long-term results following Keller resection arthroplasty for hallux rigidus. *Foot & Ankle International*. 2011;32:933-939.
7. Lau JTC, Daniels TR. Outcomes following cheilectomy and interpositional arthroplasty in hallux rigidus. *Foot & Ankle International*. 2001;22:462-470.

### Non-union / Malunion in first MTP Fusion

Defining non-union has its pitfalls but for present purposes could be defined as definite lack of bony bridging on radiographs or computed tomography, with no radiological progression over a three month interval. It may not necessarily be symptomatic. Mal-union again is elusive to define given that patients' acceptance of different positions can vary widely and there is no absolute range. However it is generally accepted that the toe is ideally positioned around 25 degrees dorsiflexed compared to the metatarsal (although this depends on the height of the arch) or 10 degrees dorsiflexed compared to the floor, giving it clearance in second rocker but ensuring contact in third rocker. If dorsiflexed excessively the toe will rub on shoes and there may be more sesamoid pain. The hallux lies naturally in 10-15 degrees valgus, parallel with the second toe, although in a fusion it may be desirable to leave a slight gap as the newly stiff hallux will not allow for any accommodation if the lesser toes are crowded. On the other hand, too straight an angle may lead to interphalangeal joint arthrosis. Finsen showed "only a weak correlation between position and clinical outcome"<sup>1</sup> – probably because there are so many other factors that affect outcome.

In a systematic review<sup>2</sup> of 37 studies and 2818 arthrodeses, there was a 5.4% non-union rate; only a third of them were symptomatic. Mal-union was judged to be present in 6.1%. There are patient related factors and surgeon related factors<sup>3,4</sup>.

#### Patient factors

Patient factors	Pathology	Rheumatoid Revisions Use of bone block
	Smoking	Three times risk of non-union in foot and ankle arthrodeses <sup>5</sup>
	Diabetes	Increases time to union and rates of non-union <sup>6,7</sup>
	Medication	NSAIDs – conflicting evidence but prudent to avoid Corticosteroids – slow union in rats
Surgical factors	Technique	Joint preparation Fixation
	Post-op protocol	Weight-bearing Splintage

Fixation can be with:

- A single screw (including intramedullary)
- Crossed screws
- Parallel screws
- Staples
- Dorsal Plate: Locked or Non-locking
- Dorsal plate and oblique compression screw

Of these, a dorsal plate and lag screw has been shown to be the strongest construct<sup>8</sup>. However in the systematic review<sup>2</sup>, non-union rates were only higher for a single screw:

- Single screw: 8.7%
- Crossed screws: 4.9%
- Parallel screws: 0% (only 22 patients)
- Dorsal plate +/- lag screw: 5%
- Staples: 5%

Conservative treatment of non-union and mal-union involves altering shoes, adding stiffness or a rocker to the sole. As surgical treatment, Saxby showed that removal of metal was a worthwhile and simple measure, with 66% of patients satisfied after that procedure alone<sup>9</sup>.

If this fails or is predicted to fail, the non-union should be taken down, the joint re-prepared and fixed, with or without bone graft. If there is bone loss then an iliac crest bone block is the commonest method of restoring first ray length and may have an 80% rate of union<sup>10</sup>.

“Drilling and grafting” is a technique first described by Dennis in 1895 in Philadelphia and popularized by Böhler in the 1930s<sup>11</sup>. Mr Rudge presented two cases he has treated with this technique, revising the fixation only if necessary. Fluoroscopically guided drilling across the non-union site allows insertion of a core of bone harvested from the heel into the drill hole. In both cases this appeared to foster solid union by three to four months. The technique avoids fully opening and revising the joint, and so may be useful in selected cases where there is non-union but the position and fixation are acceptable.

## **Discussion**

All surgeons present performed first MTP fusions routinely.

There was unanimous consensus that intra-operative simulated weight bearing is mandatory when positioning the hallux for a fusion.

0% use a solitary screw for fixation

17 (50%) use two screws, crossed or parallel

1 (3%) use a compression screw with a non-locked plate

12 (35%) use a compression screw with a locked plate

0% would use a dorsal plate alone as it was felt that this leads to a plantar gap and higher non-union.

There was lively debate as to whether two screws or a screw and plate provided better fixation, with no consensus.

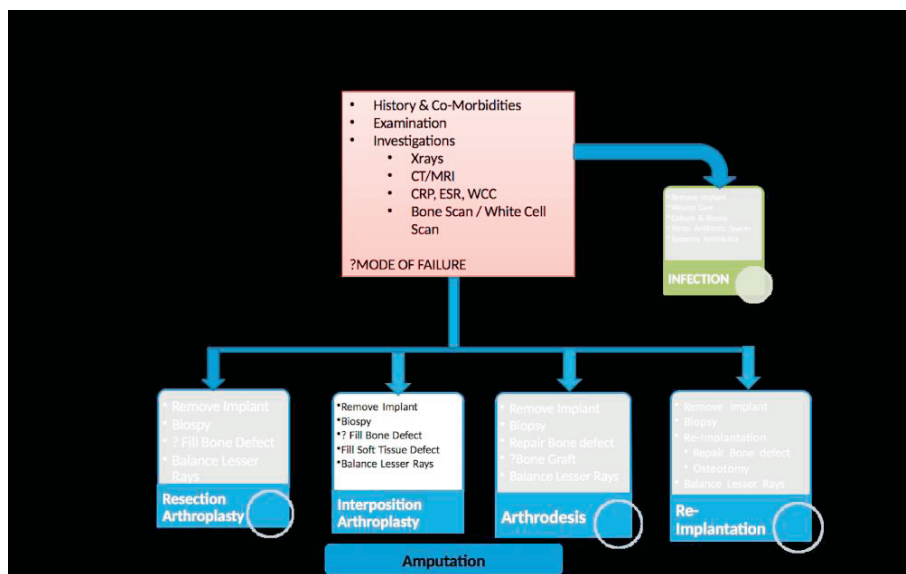
## References

1. Aas M, Johnsen TM, Finsen V. Arthrodesis of the first metatarsophalangeal joint for hallux rigidus—optimal position of fusion. *The Foot*. 2008;18:131-135.
2. Roukis TS. Nonunion after arthrodesis of the first metatarsal-phalangeal joint: a systematic review. *The Journal of Foot and Ankle Surgery*. 2011;50:710-713.
3. Thevendran G, Younger A, Pinney S. Current Concepts Review: Risk Factors for Nonunions in Foot and Ankle Arthrodeses. *Foot & Ankle International*. 2012;33:1031-1040.2.
4. Gaston MS, Simpson AHRW. Inhibition of fracture healing. *Journal of Bone & Joint Surgery, British Volume*. 2007;89:1553-1560.
5. Cobb TK, Gabrielsen TA, Campbell DC, Wallrichs SL, Ilstrup DM. Cigarette smoking and nonunion after ankle arthrodesis. *Foot & Ankle International*. 1994;15:64-68.
6. Perlman MH, Thordarson DB. Ankle fusion in a high risk population: an assessment of nonunion risk factors. *Foot & ankle international*. 1999;20:491-496.
7. Loder RT. The influence of diabetes mellitus on the healing of closed fractures. *Clinical orthopaedics and related research*. 1988;232:210-216.
8. Politi J, Hayes J, Njus G, Bennett GL, Kay DB. First metatarsal-phalangeal joint arthrodesis: a biomechanical assessment of stability. *Foot & ankle international*. 2003;24:332-337.
9. Hope M, Savva N, Whitehouse S, Elliot R, Saxby TS. Is it necessary to re-fuse a non-union of a hallux metatarsophalangeal joint arthrodesis? *Foot & Ankle International*. 2010;31:662-669.
10. Myerson MS, Schon LC, McGuigan FX, Oznur A. Result of arthrodesis of the hallux metatarsophalangeal joint using bone graft for restoration of length. *Foot & Ankle International*. 2000;21:297-306.
11. Bohler, Lorenz : Pseudoarthrosen beandlung mit der Beck'schen Bohrung. *Zentralbl. f. Chir.*, 57, I654, 1930.

## Revision of the failed MTP implant and failed Keller's

MTP arthroplasty may fail due to pain, infection, wear, loosening, fracture and transfer pain and other biomechanical disturbances. As well as history, examination, radiographs and CRP, computed tomography, magnetic resonance imaging or bone scan can all give useful information. In approaching this challenge, the principal aims of treatment are to:

- Improve pain
- Improve mobility
- Stop bone destruction
- Stop soft tissue destruction
- Clear infection
- Restore foot mechanics
- Preserve motion if possible



Implant removal and resection arthroplasty was investigated by Kitaoka<sup>1</sup>. Ten failed Silastics were removed at an average of 3.1 yrs. The results were excellent in seven patients, good in one, fair in one and poor in one. The main problems in the latter were Hallux Elevatus and Transfer Metatarsalgia. So a Keller's procedure is a very reasonable salvage operation.

With interposition arthroplasty, the implant is removed, synovectomy performed and soft tissue inserted in the joint as "anchovy interposition". Suitable grafts include EHB tendon, plantaris, hamstring or joint capsule. A similar idea using the "Graft Jacket" as a spacer yielded a good result in one case, where the whole proximal phalanx had been eroded<sup>2</sup>. However, it is difficult to see how any

of these procedures re-function the first ray, given that they take away length and de-tension the extrinsic tendons.

Re-Implantation was investigated by Hariharan<sup>3</sup> in 2004. Silastics were removed and the MOJE implanted in seven feet. At 18 months' follow up their AOFAS scores were acceptable and the procedure was deemed safe. Koenig<sup>4</sup> similarly removed silastic implants and implanted the Biomet Total Toe replacement with good results at 12 months in nine out of ten patients. Both these studies have short follow up times.

Iliac Crest Bone Graft Arthrodesis was investigated as a technique by Brodsky<sup>5</sup> in 2000. Twelve patients underwent the surgery, eight for a failed MTPJ Implant. Eleven of twelve achieved union at an average of fifteen weeks, and were not pain-free but were said to have minimal pain. Patients were living independently but not able to indulge in sport. Transfer pain was relieved. There were three major complications: two with skin necrosis (presumably due to tension) and one with non-union and a broken plate.

For the salvage of the painful Keller's arthroplasty, Coughlin and Mann<sup>6</sup> performed 16 arthrodeses of the 1<sup>st</sup> MTP joint, four with intercalary bone graft. They report a 100% union rate, good relief of transfer pain, and all patients satisfied. In another study<sup>7</sup>, this approach was contrasted with repeat Keller's arthroplasty, Z lengthening of EHL, capsular reefing and excision of the sesamoids: the fusions did relatively well with 13/29 excellent and 5/29 poor results, compared to 11/21 poor and no excellent results in the repeat Keller's group.

Therefore a pragmatic approach is suggested for failed first MTP arthroplasty. Any implant is removed and if infection is suspected or confirmed, reconstruction is delayed, with the option of inserting temporary antibiotic-loaded beads. In order to re-function the first ray for comfortable load bearing, it must be made longer and more plantar, for which intercalary bone graft fusion is ideal, using iliac crest tricortical graft. This is technically challenging, in achieving good toe alignment, matching the graft to the bony cuts, filling defects, balancing the need for length with the tension that soft tissues can tolerate, and balancing the lesser rays. If the patient's demands are low then simple removal, synovectomy and Keller's procedure is a reasonable option.

## **Discussion**

Two surgeons had used allograft iliac crest with similar results to autograft. On fixation of the iliac crest graft, many surgeons do not fix it at all, since it is difficult and there is naturally compression. Some surgeons fashion the graft into a dowel which fits inside the phalanx and the metatarsal. Others use a single compression screw across the whole construct because there is frequently delayed or non-union of the distal bone-graft interface, the literature notwithstanding.

It was pointed out that the interphalangeal joint may be stiff and painful in some of these patients which complicates their treatment. The rotation of the toe must be such that this joint is well aligned in the sagittal plane, and the distal phalanx must clear the ground in stance but allow contact during the third rocker. If painful enough it can be fused with the obvious disadvantage of a totally stiff hallux.

Of the 34 surgeons present, 20 (59%) do not perform any kind of first MTP replacement. Of the 14 who do, nine insert Silastic implants, six perform hemi-arthroplasties (with some overlap between groups) and two perform total MTP replacement. No-one present would use a ceramic implant.

## References

1. Kitaoka HB, Holiday AD, Chao EYS, Cahalan TD. Salvage of Failed First Metatarsophalangeal Joint Implant Arthroplasty by Implant Removal and Synovectomy: Clinical and Biomechanical Evaluation\*. *Foot & Ankle International*. 1992;13:243-250.
2. Khoury WE, Fahim R, Sciulli JM, Ehredt Jr DJ. Management of Failed and Infected First Metatarsophalangeal Joint Implant Arthroplasty by Reconstruction with an Acellular Dermal Matrix: A Case Report. *The Journal of Foot and Ankle Surgery*. 2012;51:669-674.
3. Sloan A, Ramaswamy R, Hariharan K. Revision arthroplasty for failed first metatarsophalangeal joint arthroplasties with ceramic arthroplasty and impaction bone grafting. *Foot and ankle surgery*. 2004;10:23-27.
4. Koenig RD. Revision arthroplasty utilizing the Biomet Total Toe System for failed silicone elastomer implants. *The Journal of foot and ankle surgery: official publication of the American College of Foot and Ankle Surgeons*. 1993;33:222-227.
5. Brodsky JW, Ptaszek AJ, Morris SG. Salvage first MTP arthrodesis utilizing ICBG: clinical evaluation and outcome. *Foot & Ankle International*. 2000;21:290-296.
6. Coughlin MJ, Mann RA. Arthrodesis of the first metatarsophalangeal joint as salvage for the failed Keller procedure. *J Bone Joint Surg Am*. 1987;69:68-75.
7. Machacek FJ, Easley ME, Gruber F, Ritschl P, Trnka HJ. Salvage of a failed Keller resection arthroplasty. *J Bone Joint Surg Am*. 2004;86-A:1131-1138.

## Floating Toe

A floating toe is a lesser toe that sits off the ground after a metatarsal shortening osteotomy (MSO) such as Weil's, Helal's, Maceira or distal minimally-invasive metatarsal osteotomy (DMMO). It is a difficult problem to manage.

There are various hypotheses explaining floating toes. Trnka et al<sup>1</sup> proposed that shortening changes the action of the lumbricals and interossei from flexors to extensors. Dampening of the windlass mechanism was proposed by Perez et al<sup>2</sup>. Additional factors in floating toe are thought to be the presence of a plantar plate tear, the type of osteotomy that was performed, whether a PIPJ arthrodesis was required as well (makes floating toe more likely) and how the toe was splinted post-operatively.

To combat excessive shortening one could aim for less than 3mm shortening of Weil's osteotomies, double-cutting to focus on elevation rather than shortening; or one could use a Maceira cut, which has also been called a triple cut Weil osteotomy.

Floating toes are common, with Highlander et al.<sup>3</sup> reporting a 36% rate in 1131 cases. Hofstaetter et al.<sup>4</sup> reported a 68% rate in 25 cases with seven year follow up.

To prevent a floating toe after a MSO, something must hold the toe down at the MTP joint. A K-wire across the flexed joint will provide reliable splintage for a few weeks. Plantar plate repair or advancement may be tried, or flexor to extensor transfer (effectively converting FDB tendon into a flexor of the MTPJ, like the intrinsic muscles)<sup>5</sup>. A similar concept is FDB transfer to the proximal phalanx<sup>6</sup>. Chalyan et al<sup>5</sup> performed a biomechanical study on cadavers, testing resistance to dorsiflexion and dorsal subluxation of the toe. They found that flexor to extensor transfer added to MTPJ stability following Weil osteotomy. If the plantar plate was disrupted, Weil osteotomy left the joint very unstable.

There is debate about whether the plantar plate should be repaired if torn, should be advanced in all cases or never repaired at all. It is recognised that there is an increased incidence of floating with PIPJ arthrodesis, which may relate to K-wires over-straightening; a good reason to consider a PIP fusion implant. On the other hand, if a K-wire is used and driven across the MTP joint as well, the joint may be protected from subluxation long term. Alternatively a blocking K wire can be used dorsal to the toe without transfixing it.

Intuitively, post-operative splinting (or lack of it) would also affect outcome. A recent study of 30 patients demonstrated that a special splint (made by Darco) resulted in 0 cases of floating toe, but without the length of follow up of the older studies<sup>7</sup>.

There is little in the literature about treating floating toes. A flexor to extensor transfer or plantar plate advancement may be tried but at the expense of stiffness, which is inevitable<sup>8</sup>. Ideally floating toes are prevented, as above, by avoiding excessive shortening, considering flexor to extensor transfer if shortening more than 3mm, considering plantar plate advancement if that pathology is suspected, and aggressive post-operative splinting and manipulation.

### Discussion and consensus

All present sometimes use Weil osteotomies except one surgeon who uses Maceira osteotomies. 23 out of 34 surgeons (68%) sometimes perform double cut Weil osteotomies to avoid plantarising the lesser metatarsal head, while one surgeon performs a double cut to prevent floating toe.

There was agreement that post-operative dressing or taping is important to prevent the toe from rising. The dorsal scar may otherwise contract and contribute to floating.

Thirteen out of 34 surgeons (38%) were performing plantar plate repairs, but of these thirteen, eleven expressed dissatisfaction with the procedure, illustrating that this is not a settled question. Tightening and stiffening of the MTP joint were concerns for several surgeons as they felt that patients prefer floppy to stiff toes. There was also disagreement about the reliability of translational pain or the “mini Lachmann test” of the toe as a diagnostic test for plantar plate pathology.

It was proposed that a floating toe may arise when only one ray is shortened and the others left behind, de-tensioning the soft tissues of the operated toe alone as the tendons of FDL are bound to each other as well as to FHL at the knot of Henry. A solitary Weil osteotomy may also risk transfer pain on to the adjacent ray; three surgeons (9%) as a rule therefore tended not to do solitary Weil osteotomies, whereas the rest would sometimes do them. Some surgeons found that soft tissue releases around the MTPJ were usually enough to bring down a hyperextended toe, without having to shorten the metatarsal as well. Others favoured a Stainsby procedure with generous resection of most of the proximal phalanx to treat both PIP and MTP deformity at once.

It was generally acknowledged that distal metatarsal osteotomies are difficult technically, particularly when judging how much to take off in a double cut, and care must be taken not to plantar flex the head. An intra-operative skyline view of the forefoot may help judge the relative height of the metatarsal heads, as well as a dorso-plantar view to judge the metatarsal cascade in the transverse plane.

## References

1. Trnka HJ, Nyska M, Parks BG, Myerson MS. Dorsiflexion contracture after the Weil osteotomy: results of cadaver study and three-dimensional analysis. *Foot Ankle Int.* 2001;22:47-50.
2. Perez HR, Reber LK, Christensen JC. The role of passive plantar flexion in floating toes following Weil osteotomy. *J Foot Ankle Surg.* 2008;47:520-526.
3. Highlander P, VonHerbulis E, Gonzalez A, Britt J, Buchman J. Complications of the Weil osteotomy. *Foot Ankle Spec.* 2011;4:165-170.
4. Hofstaetter SG, Hofstaetter JG, Petroutsas JA, Gruber F, Ritschl P, Trnka HJ. The Weil osteotomy: a seven-year follow-up. *J Bone Joint Surg Br.* 2005;87:1507-1511.
5. Chalayan O, Chertman C, Guss AD, Saltzman CL, Nickisch F, Bachus KN. Role of plantar plate and surgical reconstruction techniques on static stability of lesser metatarsophalangeal joints: a biomechanical study. *Foot Ankle Int.* 2013;34:1436-1442.
6. Lee LC, Charlton TP, Thordarson DB. Flexor digitorum brevis transfer for floating toe prevention after Weil osteotomy: a cadaveric study. *Foot Ankle Int.* 2013;34:1724-1728.
7. Godoy-Santos AL, Diniz Fernandes T, Luzo C, Ortiz RT, Sakaki M, Weil LJ. Effectiveness of the Dorsal Thermoplastic Locking Orthosis to Prevent Floating Toes in Postoperative Follow-up of Weil Osteotomies: Pilot Study. *Foot Ankle Spec.* 2014;7:356-362.
8. Myerson MS, Jung HG. The role of toe flexor-to-extensor transfer in correcting metatarsophalangeal joint instability of the second toe. *Foot Ankle Int.* 2005;26:675-679.

## Floppy or Short Toes After Surgery

Coughlin wrote that a floppy or flail toe is “*one of the most difficult complications*”. It is an iatrogenic condition in which the digit lacks structural stability. It is usually a result of excessive resection of the distal aspect of the proximal phalanx during correction of a claw or hammer toe deformity. It is not the same as a floating toe where the toe fails to purchase the ground<sup>1</sup>.

The patient may complain of poor cosmesis, toes that press on the toe box of the shoe, weakness of lesser toe push off in 3rd rocker, and awkwardness putting on socks. Clinically the toe is hypermobile and in particular hyper-extensible.

Floppy toes could be classified according to whether too much bone was taken (hard) or tendons released too keenly (soft), as follows:

- Hard – Type 1, after hammer toe correction with aggressive resection of the distal end of the proximal phalanx
- Hard – Type 2, excessive resection of the metatarsal head
- Soft – overzealous release of EDB and EDL.

Like all iatrogenic problems, the best treatment is prevention. Conservative measures would include shoes with a wide, high toe box. Surgical repair options include;

- Revision PIP fusion with structural bone graft
- Revision fusion with an implant.
- Syndactylization.
- V-Y Plasty.
- Amputation.

Revision PIP fusion with an implant may be suitable for “Hard Type 1” floppy toes but the patient may well need new bone stock. A retrospective review of 22 flail toes in 13 patients reported an 82 % success rate, performing one-stage digital lengthening with autologous bone from the ipsilateral calcaneus<sup>2</sup>.

An over shortened metatarsal (“Hard Type 2” toe) requires re-balancing of the metatarsal cascade, with shortening osteotomies to the other metatarsals.

Syndactylization is an established treatment for congenital crossed toes<sup>3</sup> but not for flail toe. It is, in theory, a reasonable, if drastic, solution for any of the types of floppy toe.

Soft Tissue V-Y plasty involves soft tissue release and a skin procedure, with or without resection of part of the metatarsal head. There are case series but it does not address the shortening or instability of the toe<sup>4,5</sup>.

If there is lack of EDB and EDL (“Soft” type floppy toe), adhesiolysis, Z shortening or free EDB graft could be considered, but there are no published case series of these techniques.

Amputation of the toe is a salvage technique for both hard & soft types with which every surgeon will be familiar, and yet case series for this procedure have not been published. Cosmesis is obviously affected and there is a risk of hallux valgus after second toe amputation, so this option tends to be reserved for the elderly, or for those who do not want complicated surgery with a prolonged recovery.

In summary, flail toes should be avoided by resecting bone judiciously and taking care when lengthening the extensor tendons. For surgical revision of “Hard Type 1” flail toe, what little literature exists supports PIP fusion with block bone graft; for “Hard Type 2” we should restore the metatarsal cascade, and for “Soft” flail toe there is no established solution, but soft tissue correction may reasonably be attempted. Salvage options are syndactylization or amputation of the toe.

## References

1. McGlamry ED. Floating toe syndrome. J Am Podiatry Assoc. 1982;72:561-568.
2. Mahan KT, Downey MS, Weinfeld GD. Autogenous bone graft interpositional arthrodesis for the correction of flail toe. A retrospective analysis of 22 procedures. J Am Podiatr Med Assoc. 2003;93:167-173.
3. Rao GS, James JH. Artificial syndactylisation for congenital crossed toes. Br J Plast Surg. 1987;40:502-504.
4. Friend G. Correction of iatrogenic floating toe following resection of the base of the proximal phalanx. Clin Podiatr Med Surg. 1986;3:57-64.
5. Pichney GA, Derner R, Lauf E. Digital "V" arthrodesis. J Foot Ankle Surg. 1993;32:473-479.

## **Non-union, malunion and avascular necrosis after Weil or Distal Minimally invasive Metatarsal Osteotomies**

Non-union and AVN after Weil osteotomy are extremely rare – the author having only ever seen two non-unions. Only four delegates had encountered AVN and there are only a few cases in the literature<sup>1</sup>. Non-union used to be common with the more proximal Helal osteotomies, which frequently required plaster immobilisation and sometimes plating. The problems with Weil osteotomies are in planning which “normal” rays to operate on as demanded by some of the philosophies in forefoot reconstruction; how to correct varus and valgus toes (moving the head into the concavity of the deformity does not always work); avoiding stiff or floating toes; and avoiding causing malunion and transfer pain by inadvertently moving the metatarsal head plantar-wards.

### **Consensus:**

DDMO's are not yet mainstream (only four of 34 delegates perform them).

Avoiding malunion is about good technique (keeping the saw blade parallel to the sole), doing a double cut, particularly on the lateral rays, checking fluoroscopic images on the table, and feeling the foot for prominence of the metatarsals on the table. The last is a cost-free form of pedobarography.

### **Consensus:**

Seventeen surgeons (50%) always X ray Weil osteotomies intra-operatively; seven (21%) sometimes do and eight (24%) never do.

To avoid stiffness, a more extensive decompression and patient led toe exercises both help. For most patients, physiotherapy may not be any better than the surgeon teaching the exercises, but it can be useful in reluctant patients. Patients should be warned that If stiffness does settle, it is often worthwhile removing the screws and adding a synovectomy and adhesiolysis at 6 to 12 months.

Accepting then that Weil osteotomies are not without potential problems, one alternative is the aforementioned Helal osteotomy. Trnka in 1996<sup>2</sup> reported 61% excellent or good results, but 22% had transfer lesions, 5% non-unions and 10% delayed unions. Winson et al<sup>3</sup> studied 124 feet in 93 patients who had undergone a sliding Helal metatarsal osteotomy at an average of 3.4 years. 19% had poor results and 14% had required a revision procedure. 40% had symptomatic plantar callosities. Poor results were associated with age >65, the addition of first and fifth metatarsal osteotomies, and the use of plaster immobilization. A fixed claw toe was a common sequela of the surgery. By contrast Davies et al<sup>4</sup> reviewed their series of what were essentially Weil's in 47 feet and found 77% pain free at around a year, with only one union delayed beyond 6 weeks. They felt stiffness was not a problem with aggressive physiotherapy.

Trnka in 1999<sup>5</sup> directly compared Helal and Weil osteotomies and found the latter had higher patient satisfaction; less recurrent metatarsalgia (0 vs 27%), fewer transfer lesions (0 vs 41%), fewer non unions (0 vs 5) and fewer pseudarthroses (0 vs 3). At 7 years follow up after Weil's, Hofstaetter and Trnka<sup>6</sup> found 88% excellent or good results, but 12% had redislocated and were “floating”. They associated failure with inadequate shortening.

A DMMO is essentially a percutaneous, quick osteotomy, generally performed with a burr and not fixed with metalwork, and is distal to where Helal's were performed. Being in metaphyseal bone they generally unite. In a comparison of 39 DMMO and 33 Weil<sup>7</sup>, there was little difference except that the DMMO group recovered slightly slower and had more oedema, and possibly more delayed union. There was no significant difference in rates of stiffness, union, radiological "recoil", and transfer lesions. So there may be little to choose between the two methods.

In summary, at the moment Weil's osteotomies appear to be as good a solution as any for lesser MTPJ problems. The speaker advocates being aggressive with the degree of shortening and number of rays shortened, using a double cut often, and always with the 4<sup>th</sup> and 5<sup>th</sup> rays, and being ready to remove metalwork and release the dorsal scarring for cases of stiffness.

## References

1. Bayliss NC, Klenerman L. Avascular necrosis of lesser metatarsal heads following forefoot surgery. *Foot Ankle*. 1989;10:124-128.
2. Trnka HJ, Kabon B, Zettl R, Kaider A, Salzer M, Ritschl P. Helal metatarsal osteotomy for the treatment of metatarsalgia: a critical analysis of results. *Orthopedics*. 1996;19:457-461.
3. Winson IG, Rawlinson J, Broughton NS. Treatment of metatarsalgia by sliding distal metatarsal osteotomy. *Foot Ankle*. 1988;9:2-6.
4. Davies MS, Saxby TS. Metatarsal neck osteotomy with rigid internal fixation for the treatment of lesser toe metatarsophalangeal joint pathology. *Foot Ankle Int*. 1999;20:630-635.
5. Trnka HJ, Muhlbauer M, Zettl R, Myerson MS, Ritschl P. Comparison of the results of the Weil and Helal osteotomies for the treatment of metatarsalgia secondary to dislocation of the lesser metatarsophalangeal joints. *Foot Ankle Int*. 1999;20:72-79.
6. Hofstaetter SG, Hofstaetter JG, Petroutsas JA, Gruber F, Ritschl P, Trnka HJ. The Weil osteotomy: a seven-year follow-up. *J Bone Joint Surg Br*. 2005;87:1507-1511.
7. Henry J, Besse JL, Fessy MH. Distal osteotomy of the lateral metatarsals: a series of 72 cases comparing the Weil osteotomy and the DMMO percutaneous osteotomy. *Orthop Traumatol Surg Res*. 2011;97:S57-S65.

## Achilles Tendon Rupture

Surgical and conservative management of an Achilles tendon rupture can give equivalent re-rupture rates (1). However there are multiple other endpoints to consider including gastro-soleus function and wound breakdown which can have a considerable impact the final outcome of our treatment.

### **Consensus on Current practice 2014: *Choice of treatment***

In the average patient, 50% would obtain an ultrasound to assess if the torn ends appose on plantar flexion. Failure for ends to oppose would be seen as an indication for surgical intervention

### **Consensus on Current practice 2014: *Conservative management***

10% Cast only

10% Boot/ splint only

65% cast for 2 weeks then boot/ splint

15% attendees did not vote

Nearly all attendees allow full weightbearing in boot/splint

### **Consensus on Current practice 2014: *How would you treat an active sporty fit and well 40 yr old patient who presents day 1?***

25% Conservative management

25% No strong feelings

50% Surgical treatment

### **Current practice 2014: How would you treat an elite athlete presenting on day 1.**

95% Surgical treatment

5% Conservative

### **Current practice 2014: Suture type for repair**

65% Absorbable

35% Non-absorbable

Whilst the general consensus was to use an absorbable suture, it was highlighted there are other suture factors that are important such as whether it is braided or not; not all absorbable sutures are equal. An absorbable suture induces an inflammatory reaction but an inert suture material forms a foreign body that was felt to be the cause of post-operative complications seen after Achilles surgery. A braided suture used in a locking pattern such as the Krackow suture, may get better “grip” of the tendon ends when compared to a non-locked or monofilament suture.

## **Current practice 2014: Method of repair**

35% Mini-invasive

65% Open

## **Re-rupture**

This can broadly be defined as a recurrent Achilles tendon rupture within 6 months of an adequately treated primary rupture. It is thought to occur in between 5-10% of patients and depends on many factors including the function/ compliance of the patient and the primary rupture treatment.

There is little evidence in how best to treat these patients although the general consensus was to offer a different method treatment and rehabilitation.

## **Achilles length**

Ruptured tendons treated either surgically or conservatively can heal elongated or tight with residual equinus. Usually this is either due to improper tensioning during surgery or over stretching during rehabilitation.

Other than tibio-talar impingement the Achilles tendon is the main restrictor to ankle dorsiflexion and thus the range of dorsiflexion is a reliable test for Achilles length, when compared to a normal side. A difference of 10 degrees is thought to be significant.

### *Lengthened tendon*

This often correlates to a poor clinical outcome and patients may complain of gait disturbance with weakness in end-range plantar flexion, during the third rocker. Care should be taken in the management of Achilles ruptures to avoid a lengthened tendon. USS may highlight a gap, predicting increased length once healed, although the effect of this on final function has not been clinically quantified. Equally during surgical repair the tendon grasping suture needs to be locked to avoid slipping or stretching during rehabilitation.

The long tendon can be shortened surgically by procedures such as a Z shortening, however whilst such may help with the gait disturbance they do not offer a significant improvement in isokinetic gastro-soleus strength (2,3).

### *Shortened tendon*

When there is symptomatic shortening surgical lengthening with either a Z lengthening and side to side repair or other technique is a possible solution.

A stiff ankle or lack of dorsiflexion beyond 10 degrees of fixed plantar flexion will overload the forefoot and will affect the second rocker of gait. This may be prevented during surgical treatment by thorough division of adhesions, tying knots away from the rupture site and meticulous epitendonous repair. Also regular progression from equinus to neutral during functional rehabilitation is essential.

## **Wound healing**

There is little in the literature to highlight how best to manage this difficult complication of surgical management. Wounds can be a problem after various forms of Achilles surgery, but are commonest (5-10%) after traumatic rupture repair or reconstruction.

Scars around the achilles can be painful and tender or hypertrophic especially in the insertional area. The wound edges can necrose or there can be necrosis of the whole soft tissue covering the Achilles. Infection, when it occurs, can be superficial or deep.

Some of these problems can be avoided by meticulous surgical technique. Thick soft tissue flaps with an incision placed away from the midline can avoid interference with footwear. Others have changed to use percutaneous techniques.

**Current practice 2014:** Use of percutaneous Achilles repair

60% regularly use an open repair

40% regularly use a percutaneous technique

50% of these use transverse skin incisions

50% of these use longitudinal incisions

However there will be a time that despite good technique a wound infection occurs. Clearly there are many host factors that are important with diabetics, smokers and those on steroids up to 8X more likely to get an infection.

**Current practice 2014:** experience of wound healing problems

50% had experienced wound healing problems in Achilles surgery patients

Infection can be divided into superficial or deep wound problems and may be fungal as well as bacterial. All problematic wounds should undergo microbiological swab for MC+S and fungal scrapings/culture.

Deep infection needs to be treated in conjunction with a plastic surgeon. It may be a case of debriding the wound and then undergoing a period of “dress & suppress” whilst it granulates. In the case of requiring deep and extensive soft tissue debridement any tendon defect should be assessed. This defect may then require reconstruction with a V-Y plasty, tendon grafting or transfer of peroneus brevis or FHL, as well as a skin graft or fasciocutaneous flap.

## **Consensus on management of achilles tendon ruptures**

- Length of treatment >6 weeks
- Conservative management: Cast for 2 weeks covered by LMWH prophylaxis. Progress into splint or boot weight bearing immediately. No need for prolonged LMWH
- Surgical management: Non-midline incision or percutaneous, longitudinal incisions and debridement of adhesions. Meticulous soft tissue handling. Use of the thickest, braided, bio-absorbable suture available. Kessler or Krackow grasping suture technique, knots away from rupture, tensioned properly to correct length. Epatendonous repair. Same rehabilitation as conservative.
- If too long or too short, then whilst length can be corrected the strength will usually not return.

- Patients should be counselled fully for the risks of re-rupture and wound problems

## References

1. J Bone Joint Surg Am. 2012;;94(23):2136-43
2. Bohnsack et al Z Orthop Ihre Grenzgeb. 2000 Nov-Dec;138(6):501-5
3. Maffulli et al Int Orthop. 2012 Oct;36(10):2087-93

STC

## Persistent Flat Foot after Tibialis Posterior Tendon Surgery

As a flat foot deformity progresses the position of the forefoot in relation to the hindfoot changes. In the correction of the flat foot it is important to assess and correct each deformity. Failure to achieve this at the time of surgery may lead to a persistent flat foot deformity, which may or may not be symptomatic.

Repair of the tibialis posterior tendon is seldom sufficient in isolation and an FDL tendon transfer needs to be augmented with a boney procedure. At the same time any subtalar deformity needs to be reduced with a spring ligament reconstruction +/- a further boney procedure. It is this subtalar reduction that restores the shape of the foot.

**Current practice 2014:** Surgery in stage II deficiency – spring ligament

95% routinely reconstruct the spring ligament

This then should be augmented by either a medial displacement calcaneal osteotomy or by a lateral column lengthening and can also be protected with an arthroereisis screw and/ or a gastrocnemius recession. The choice between these procedures will depend on the surgeon, the extent of midfoot abduction and the pitch of the calcaneus.

**Current practice 2014:** Surgery in stage II deficiency – Lateral column lengthening

45% do very rarely

55% have done on occasion

For a calcaneal osteotomy to work it requires a normal pitch of the calcaneus and it has no effect on the talo-navicular joint, thus the TN joint needs to be normal. When the calcaneal pitch is low a lateral column lengthening restores foot shape and reduces the TN joint subluxation. In adults there is a 10-

20% risk of non-union with a lateral column lengthening and therefore it is best selected for the younger adult and the non-smoker. In the older patient or a smoker a subtalar fusion may be more appropriate. When performed care should be taken to first reduce the ST joint and not just fuse in situ, as it is the reduction of the subtalar joint that reduces the TN joint.

**Current practice 2014: Surgery in stage II deficiency – Arthroereisis screw**

10% use to protect reconstruction

Although seldom used amongst those present it was generally felt that this screw holds the reduction of the subtalar joint, but that it only works in conjunction with other procedures. When used the screw is often symptomatic and thus routine removal at 6 months following reconstruction is advised.

**Current practice 2014: Surgery in stage II deficiency – Gastrocnemius recession**

65% perform a recession in the majority of cases

This can be performed in the body of the muscle/ fascia or by medial head release. It may be best to perform this at the start of reconstruction to allow full correction of hindfoot deformity.

Once the hindfoot position has been corrected any midfoot and forefoot correction should be performed. This is performed where the midfoot break is, whether this is the TN or NC joints.

**Consensus on stage II flat foot correction**

1. Gastrocnemius recession
2. FDL tendon transfer
3. Spring ligament reconstruction
4. Calcaneal osteotomy or lateral column lengthening
5. Arthroereisis screw by some present

## Peroneal Tendon Surgery

In the management of ongoing symptomatic peroneal tendon pathology it is vital to highlight what you are trying to treat. There are five main problems that we see:-

- Pain
- Instability
- Split tears
- Single complete tear
- Double tears/ revision

In the presence of painful tendonopathy, injection of LA +/- steroid can both be diagnostic and therapeutic, although this is not risk free.

**Current practice 2014:** Injection of peroneal tendon/ sheath

65% are happy to use injections

90% of these are USS guided

20% have seen iatrogenic tendon rupture after injection

10% of those who use injections advise a brace afterwards

An unstable tendon(s) need to be stabilised and this can be achieved by either soft tissue reconstruction or by deepening the peroneal groove. When recurrent, a tendo-achilles graft has been shown to be beneficial (1).

When the tendon is torn it is vital to highlight whether this is complete or incomplete and which tendon(s) is/are affected. Incomplete or spit tears tend to be longitudinal and thus can be treated by decompression/ synovectomy, peroneal tubercle excision and low lying muscle belly resection, even if recurrent.

Isolated ruptures of peroneus longus are unusual, but when they do occur the distal stump retracts deep into the plantar aspect of the foot. In the absence of PL there may be little functional deficit other than metatarsus elevatus. In a complete rupture of peroneus brevis the tendon stump is easy to retrieve and should undergo tenodesis to the adjacent PL tendon as long as it is intact.

When both tendons are torn it is more difficult to treat. This can either occur as the primary pathology or in a single tendon which has undergone a tenodesis in the past. In this situation reconstruction with FHL along with distal stump tenodesis is advised. This then balances the pull of tibialis posterior and doesn't tend to require the addition of a split tibialis anterior transfer.

### Consensus on persistent problematic peroneal tendons

- Pain –USS guided injection
- Instability – Re-stabilise +/- augment with graft
- Split tears – Tubularise +/- tenodesis
- Single complete tear- Tenodesis
- Double tears/ revision – FHL transfer

### Reference

1. FAS:1999 267-270

## Failed Lateral Ligament Reconstruction

Consensus was previously reached on surgery for lateral ligament reconstruction in Barcelona 2013.

70% would re-do a modified Brostrom

There are multiple reasons for failure of a stabilisation procedure but they can broadly be grouped into

- Genuine repeat injury
- Missed pathology
- Technical failure

A primary modified Brostrom repair has a 80-90% success rate. If after surgery and full rehabilitation there is symptomatic instability or ongoing pain there may be alternative pathology that is contributing that also needs to be addressed. Some are very common such as peroneal tendon pathology seen in approximately 1 in 3 patients with ankle instability and others like lateral process fractures and subtalar instability are rarer but have similar symptoms and signs to those of ankle instability. Thorough examination and investigation is therefore paramount with XR including stress views, MRI and CT +/- arthrogram where appropriate.

Incidence of other pathology in chronic lateral ankle ligament instability (1):

- |                           |     |
|---------------------------|-----|
| • Peroneal tendon injury  | 28% |
| • Os trigonum             | 13% |
| • Lateral gutter ossicles | 10% |
| • Varus                   | 8%  |
| • Anterior osteophytes    | 3%  |
| • Tarsal coalition        | 2%  |

When there is true persistent or recurrent ankle instability after a modified Brostrom procedure and failed instability rehabilitation then the surgical approach should be:-

- Ankle arthroscopy
- Redo modified Brostrom/ direct repair
  - + Anatomical augmentation
  - +/- Extra-anatomical tenodesis with hamstring or synthetic ligament

The choice of material for augmentation varies from autograft or allograft semitendonosis, peroneus brevis, palmaris longus tendon to synthetic ligaments

**Current Practice 2014:** Use of autograft for augmentation of redo lateral ligament reconstruction

35% use peroneus brevis attached distally

15% use peroneus brevis not attached

20% use hamstrings

10% use allograft (Mostly USA)

Use of the posterior half of peroneus brevis allows the intact anterior portion to hypertrophy over the following years, reducing the deficit from its harvest.

## **References**

1. Chronic lateral ankle instability & associated conditions: a rationale for treatment. Strauss, Forsberg, Lippert. FAI 2007 Oct;28(10):1041-4.

## Failed Treatment of Osteochondral Defects of The Ankle

Management of osteochondral defect of the ankle is dependent on chronicity, size and position on the talar and tibial surfaces. In contained defects where the fragment cannot be fixed, microfracture or abrasion arthroplasty is seen as the gold standard treatment. This is usually performed arthroscopically and when performed adequately can have good initial results in 80% of cases.

### Current practice 2014: Ankle microfracture

35% would use abrasion arthroplasty

65% would perform microfracture

60% would perform microfracture with a pick

40% would perform microfracture with a k wire

### Current practice 2014: unstable but intact cartilage

10% would debride and microfracture

90% would leave intact

However not everyone will have a good outcome and the majority of patients who have ongoing symptoms following primary microfracture treatment will have repeat surgery although this is of no proven benefit if the primary surgery has been done adequately. Even in those who do have a good outcome, 50% need further surgery in the next 10-15 years (Bristol Group). In those who have ongoing pain the presence of other pathology such as OA, inflammatory arthritis or other intra/ extra-articular causes need to be discussed.

At RNOH Stanmore from 2005-2013 there were 30 patients referred for failed treatment of their OCD. Within this group there was a male to female ratio of 2:1 and most had undergone 2 previous microfracture procedures (range 1-5). They performed ACI/ MACI in 13/30, Hemicap 8/30, Chondron 7/30, and CICR in 2/40. At a mean of three years 48% still have pain.

### Consensus

- Microfracture is gold standard primary treatment with pick or wire
- In the investigation of these lesions a CT/ CT arthrogram in plantar flexion should be performed. There is no role for MRI or SPECT CT.

## Malunion Ankle Fracture and Failed Syndesmosis Repair

Ramsey and Hamilton have described that a 1mm talar shift can lead to a 42% decrease in congruent area but no proof exists that a 1mm shift leads to post-traumatic arthritis per se. It should also be remembered that talar shift is dynamic not static.

Yablon JBJS 77 – 53 demonstrated that in perfectly fixed bimalleolar fractures, osteoarthritis was rarely seen at 6 months to 9 years. It was proposed that fibular fixation was the key factor but recent authors have suggested that the deltoid is a key determinant (Barrie).

Ankle fracture malunion is a preventable disease, with attention to the posterior malleolus, Weber C's, deltoid instability etc. The most common malunion is a short and externally rotated fibula with talar shift.

In avoiding the problems of ankle malunion and inadequate fixation of the syndesmosis, specialist foot and ankle surgeons will need to make sure the initial management of these injuries is dealt with well by their colleagues.

The simple principles, taking no short cuts, are to:

- Fix the fibula fracture
- Fix the medial side if fractured
- Be prepared to hook out the deltoid ligament from the joint if blocking reduction
- Fix the syndesmosis if necessary

To clarify this last point, Boden et al<sup>1</sup> studied syndesmosis stability in cadavers 25yrs ago, modelling pronation external rotation injuries by dividing the appropriate bones and ligaments. They concluded that if the deltoid ligament was intact and the medial and lateral fractures repaired, the syndesmosis will be stable regardless of where the fibular fracture is. If the deltoid ligament was injured and the fibular fracture was under 4.5cm from the ankle joint, fixing the fibula was enough to stabilise the syndesmosis. Van den Bekerom et al<sup>2</sup> tested this hypothesis intra-operatively in 62 patients using the "hook test" and found Boden's criteria had high specificity but low sensitivity and that a hook test sometimes showed syndesmotic instability even in fixed fibular fractures within 4.5cm of the ankle joint.

The concept of fixing the syndesmosis without fixing the fibula has crept in but this can allow non-anatomic healing and a poor clinical outcome. Obeid et al advocate<sup>3</sup> leaving "high" fibular fractures in Maisonneuve injuries, fixing the syndesmosis with a percutaneous screw, based on five cases.

### Consensus question: how high would you fix?

If a fibular fracture is up to 8cm above the plafond, all delegates would fix the fracture.

10cm above, 23/34 (68%) would fix the fibula.

With a mid-shaft fracture, 9 (26%) would fix it.

With a fracture two thirds of the way up, none of the delegates would fix it.

Ho et al<sup>4</sup> in another cadaveric study show that plating a mid-shaft fibular fracture and fixing the syndesmosis has a mechanical advantage over syndesmotic fixation alone. The former gave additional rotational stability to the ankle on cyclical loading.

In a non-randomised clinical study of twelve patients<sup>5</sup>, Pelton et al compared the approaches taken by two different teams. The group that were treated with ORIF of the fibula and two syndesmotic screws had anatomic or near anatomic reductions; the group that underwent the percutaneous technique had an unacceptable rate of malunion and diastasis and this technique was abandoned.

In treating failed syndesmotic injury, van den Bekerom, de Leeuw and van Dijk<sup>6</sup> advocate fixing if the injury is under 6 weeks old, reconstructing if under 6 months and fusing the syndesmosis if over 6 months. If there is fibular malunion, an osteotomy may be necessary to allow reconstruction or fusion of the syndesmosis.

## **Discussion**

It was pointed out that comminuted fibular fractures may be inadvertently mal-reduced and plated, making subsequent reduction of the syndesmosis impossible. So the two steps should perhaps be combined or perhaps even the order of fixation reversed. Similarly in late reconstruction, the fibular fracture is often malunited, so it should be osteotomised to allow reduction of the joint.

It was again emphasised that the deltoid ligament can be trapped in the joint blocking reduction, in which case this must be recognised and the medial side opened and cleared. Repairing the deltoid may even add welcome stability.

## **Discussion about ankle fractures**

Should you CT after fixing a Weber C fracture?

- Of those who regularly treat fractures, 5/23 (22%) surgeons routinely CT their own syndesmosis repairs post operatively.
- 6/23 (26%) sometimes do a post-operative scan.
- 12/23 (52%) do not.

Of those who scan, nine out of 11 request both ankles, while two are happy to look at one side only.

Mr Molloy pointed out that while 70% are mal-reduced on CT with a syndesmosis screw in, 80% of those self-correct once the screw is removed.

On late syndesmotic reconstruction, there was a question on approaching the 6 week to 6 month delayed pt. Van Dijk makes a point of repairing the tibiofibular ligaments as well as using a syndesmotic screw, whereas Mr Kumar finds that clearing out the syndesmosis to enable reduction leaves very little ligament left, so he relies on the screw and, in time, fibrosis.

Mr Clark presented 7 synostoses that he had done with mean 3.5 year follow up. None had ankle arthritis but all had some pain; function was acceptable but not normal.

There is a technique attributed to Chris Walker of a distal fibular osteotomy below the syndesmosis – restoring the anatomy of the tibiotalar joint without the difficulties of reducing the chronic diastasis – and the early results of six cases are promising.

### **Consensus on reconstruction of the syndesmosis**

With a splayed, symptomatic syndesmosis, how many surgeons would fuse the syndesmosis at 12 months?

- 1/32 would fuse
- 15 /32 would always do a soft tissue repair
- 9 would explore and obtain consent to do either procedure, fusing if unable to clear out the soft tissue adequately to obtain a reduction.

### **References**

1. Boden SD, Labropoulos PA, McCowin P, Lestini WF, Hurwitz SR. Mechanical considerations for the syndesmosis screw. A cadaver study. *J Bone Joint Surg Am.* 1989;71:1548-1555.
2. van den Bekerom MP, Haverkamp D, Kerkhoffs GM, van Dijk CN. Syndesmotic stabilization in pronation external rotation ankle fractures. *Clin Orthop Relat Res.* 2010;468:991-995.
3. Obeid EM, Amr M, Hirst P, Paul AS. Percutaneous fixation of Maisonneuve and Maisonneuve-type fractures: a minimally invasive approach. *Injury.* 1998;29:619-622.
4. Ho JY, Ren Y, Kelikian A, Aminian A, Charnley I, Zhang LQ. Mid-diaphyseal fibular fractures with syndesmotic disruption: should we plate the fibula? *Foot Ankle Int.* 2008;29:587-592.
5. Pelton K, Thordarson DB, Barnwell J. Open versus closed treatment of the fibula in Maisonneuve injuries. *Foot Ankle Int.* 2010;31:604-608.
6. van den Bekerom MP, de Leeuw PA, van Dijk CN. Delayed operative treatment of syndesmotic instability. Current concepts review. *Injury.* 2009;40:1137-1142.

### Experience of the delegates

Not all those present dealt with trauma. Four questions were put to the delegates.

Have you repaired a deltoid ligament acutely following trauma?

25 said yes, 1 no.

Do you do open repair?

All said yes

Have you repaired the deltoid for chronic instability following trauma?

19 yes, 5 no.

Have you dealt with non-traumatic deltoid insufficiency?

10 yes, 9 no.

### Anatomy and function

All studies agree that the deltoid is a broad, thick sheet with multiple bands. Most studies agree that there is a superficial and deep component. Cadaveric studies disagree on the different bands, showing it is difficult to separate them<sup>1-3</sup>. Parts include the deep tibiotalar ligaments, the tibionavicular ligament and the tibiocalcaneal ligament. It also attaches to the spring ligament. The strongest parts are the anterior and posterior deep tibiotalar ligaments. The (superficial) tibiocalcaneal part is also important and strong.

The functions are to limit abduction tilt of the talus and to stabilise the ankle in plantarflexion and during pronation/supination of the rest of the foot. Translation of the talus is limited by bony anatomy, not the deltoid. The deltoid also prevents malrotation of subtalar joint<sup>4</sup>.

These ligaments necessarily degenerate in Truro stage 4 acquired planovalgus foot. We may soon see this disease more with an ageing population.

### Patterns of injury

Historically deltoid injuries have been treated with neglect as it was felt that the intrinsic stability of the ankle would allow full recovery and return of stability. However, Renstrom et al<sup>3</sup> found that between 20-40% of ankle injuries presenting for medical care lead to chronic instability and disability. Deltoid injury is seen with syndesmotic injuries and up to 18% of ankle sprains<sup>6</sup>. Isolated deltoid injuries are rare and most are associated with fractures.

Chronic insufficiency is seen with posterior tibial tendon dysfunction, triple arthrodesis, and total ankle replacement.

Hintermann<sup>7</sup> wrote on the diagnosis and treatment of deltoid insufficiency and classified the tears anatomically.

- Type 1 were avulsed proximally and were the commonest, 72% in his series.

- Type 2 are torn within the substance and are the least common, 9%.
- Type 3 are distal and made up 19%.

The repair differs depending on the type.

Is this repair necessary acutely? Several studies<sup>8-11</sup> in the 1980s and 1990s concluded that it was not important to repair the deltoid acutely as long as the mortise is reduced anatomically, the fibula is fixed and the syndesmosis stabilised. Jelinek and Porter, on the other hand, stated that the advantages of open repair were that the joint was inspected for osteochondral injury, range of motion was safer earlier, and there is more chance of avoiding chronic instability<sup>12</sup>.

Chronic reconstruction is more challenging. It needs to be combined with realignment of the hindfoot if it is to last. Nelson and Younger describe repair of the superficial deltoid combined with naviculocuneiform fusion and lateral column lengthening to reconstruct a flat foot<sup>13</sup>. Deland used Peroneus Longus tendon as a graft to reconstruct deltoid<sup>14</sup>. However the procedure was difficult and one of the five cases remained in valgus tilt.

Myerson's group described a minimally invasive deltoid reconstruction for flat foot, combined with a triple fusion, with 3 failures in 8 patients<sup>15</sup>. Haddad et al<sup>16</sup> reconstructed the superficial and deep parts of deltoid using a free tibialis anterior tendon graft in six fresh frozen cadavers. The repair was tested on an Instron jig and it was found to be strong and effective *in vitro*. However in the UK tendon allografts are not widely available.

Mr Dhar presented a patient with stage 4 flat foot in whom he had done a medial calcaneal displacement osteotomy (MCDO), lateral column lengthening, deltoid and spring ligament synthetic repair and FDL transfer to reconstruct tibialis posterior. After practising it in the cadaveric lab, he obtained a durable and comfortable reconstruction.

In conclusion this is a difficult problem, and the problem of reconstructing deltoid is not yet solved.

## References

1. Milner CE, Soames RW. The medial collateral ligaments of the human ankle joint: anatomical variations. *Foot Ankle Int.* 1998;19:289-292.
2. Pankovich AM, Shivaram MS. Anatomical basis of variability in injuries of the medial malleolus and the deltoid ligament. I. Anatomical studies. *Acta Orthop Scand.* 1979;50:217-223.
3. Boss AP, Hintermann B. Anatomical study of the medial ankle ligament complex. *Foot Ankle Int.* 2002;23:547-553.
4. Michelson J, Hamel A, Buczek F, Sharkey N. The effect of ankle injury on subtalar motion. *Foot Ankle Int.* 2004;25:639-646.
5. Renstrom PA. Persistently Painful Sprained Ankle. *J Am Acad Orthop Surg.* 1994;2:270-280.
6. Lin CF, Gross ML, Weinhold P. Ankle syndesmosis injuries: anatomy, biomechanics, mechanism of injury, and clinical guidelines for diagnosis and intervention. *J Orthop Sports Phys Ther.* 2006;36:372-384.

7. Hintermann B. Medial ankle instability. *Foot Ankle Clin.* 2003;8:723-738.
8. Tourne Y, Charbel A, Picard F, Montbarbon E, Saragaglia D. Surgical treatment of bi- and trimalleolar ankle fractures: should the medial collateral ligament be sutured or not? *J Foot Ankle Surg.* 1999;38:24-29.
9. Stromsoe K, Hogevoid HE, Skjeldal S, Alho A. The repair of a ruptured deltoid ligament is not necessary in ankle fractures. *J Bone Joint Surg Br.* 1995;77:920-921.
10. Harper MC. The deltoid ligament. An evaluation of need for surgical repair. *Clin Orthop Relat Res.* 1988;156-168.
11. Baird RA, Jackson ST. Fractures of the distal part of the fibula with associated disruption of the deltoid ligament. Treatment without repair of the deltoid ligament. *J Bone Joint Surg Am.* 1987;69:1346-1352.
12. Jelinek JA, Porter DA. Management of unstable ankle fractures and syndesmosis injuries in athletes. *Foot Ankle Clin.* 2009;14:277-298.
13. Nelson DR, Younger A. Acute posttraumatic planovalgus foot deformity involving hindfoot ligamentous pathology. *Foot Ankle Clin.* 2003;8:521-537.
14. Deland JT, de Asla RJ, Segal A. Reconstruction of the chronically failed deltoid ligament: a new technique. *Foot Ankle Int.* 2004;25:795-799.
15. Jeng CL, Bluman EM, Myerson MS. Minimally invasive deltoid ligament reconstruction for stage IV flatfoot deformity. *Foot Ankle Int.* 2011;32:21-30.
16. Haddad SL, Dedhia S, Ren Y, Rotstein J, Zhang LQ. Deltoid ligament reconstruction: a novel technique with biomechanical analysis. *Foot Ankle Int.* 2010;31:639-651.

## Malleolar Fractures after Total Ankle Replacement

One of the risks of Total Ankle Replacement (TAR) is malleolar fractures. These can occur intra-operatively, early or late (>4 months).

The incidence varies between 3-20%. Likely factors include the implant, surgical experience, bone quality (lower in rheumatoid and osteoporosis), and the presence of deformity<sup>1,2</sup>.

At Wrightington the new surgeons' first 125 Mobility TAR's from 2008-2012 were monitored after Peter Wood left (who had a low fracture rate). There were six intra-operative fractures (4.8%), mostly medial. There were three early fractures (2.4%) and four late fractures (3.2%).

Intra-operative fracture is usually caused by over-distraction, or occasionally by excursion of the saw. They are easy to fix and so there is little reason not to stabilise them with a screw. It need not change the rehabilitation, which is weight bearing as tolerated in a boot for 6-8 weeks.

In early fractures, one sees callus or a hairline fracture, again usually on the medial malleolus; they are therefore often picked up retrospectively. Some may be an unnoticed intra-operative hairline fracture. They can be managed conservatively with a brace as needed or fixed percutaneously if the surgeon has misgivings about a particular fracture's stability.

Late fracture is more sinister. It tends to be a stress fracture of the lateral malleolus and is often associated with progressive valgus hindfoot deformity and deltoid instability. The Wrightington approach is to allow these to heal in a boot and then to realign the hindfoot and/or perform a supramalleolar osteotomy. There is probably a roughly 1% yearly incidence.

If both malleoli fracture many would label that a disaster, probably associated with loosening or implant failure, and a sign that the TAR has come to the end of its useful life. It is a difficult situation to retrieve without revising the entire implant.

### References

1. Lee KT, Lee YK, Young KW, Kim JB, Seo YS. Perioperative complications and learning curve of the Mobility Total Ankle System. *Foot Ankle Int.* 2013;34:210-214.
2. McGarvey WC, Clanton TO, Lunz D. Malleolar fracture after total ankle arthroplasty: a comparison of two designs. *Clin Orthop Relat Res.* 2004;104-110.

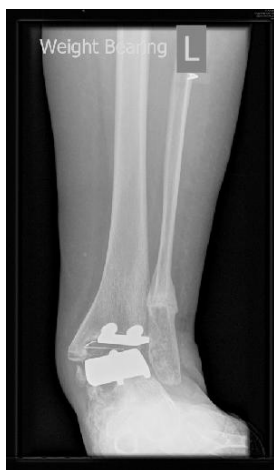

Figure: a late stress fracture

## Malalignment in Total Ankle Replacement

It is accepted wisdom that malalignment and TAR do not mix. Both the meniscus and the bone are more likely to fail if loaded asymmetrically. Early TAR series bear this concept out, but recent literature appears to show that perfect alignment is not so important.

In fact the apparent difference may relate to a change of language over the decades. Defining malalignment is not simple. There are three planes and six degrees of freedom. Osteophytes can give the false impression of malalignment; some cases are correctible with the bony cuts, others due to soft tissue laxity require a soft tissue procedure; in some patients it is the ankle itself that is malaligned, in others it is the foot beneath it. Also we tend to judge alignment from the distal tibia and assume a normal knee, but should we be measuring from the hip?

Authors should, but do not always, distinguish between pre-operative malalignment and post-operative, and state how it was measured. A common error is to call some asymmetrical medial tibial wear (which will be automatically corrected with the first tibial cut) severe varus.

We need to find out and then teach the limits on pre-operative malalignment and how it can be corrected; and improve rates of post-operative malalignment whether it be due to technique, instrument design or patient anatomy.

Early series showed that varus of over 10-15 degrees increased the failure rate<sup>1-3</sup> if not corrected. Others state that if reduced to within 10 degrees of neutral, deformity does not preclude successful TAR<sup>4-8</sup>. Corrective procedures can be staged or simultaneous and include ligament release or repair, supramalleolar osteotomy, calcaneal osteotomy and corrective triple fusion. These are demanding procedures. Correction through the tibial or talar cuts should not be dismissed as a relatively simple solution to some alignment problems.

Having said this, experienced surgeons will have seen satisfied patients with persistent deformity and TAR's lasting for many years. The clinical outcome rarely correlates with the X ray! Some recent series appear to confirm that there is not a strong correlation between deformity and failure<sup>6,9</sup>. Pre-operative deformity merely means that more corrective procedures are needed.

Other problems include coronal translation, with the talus slipping out from beneath the tibia, which will load the meniscus unevenly and impinge on one of the malleoli, but again there are examples of these patients doing well clinically. In the sagittal plane, anterior subluxation is a feature of some patients' ankle arthritis and seems worthy of correction; Lee et al<sup>10</sup> attempted to correct this, but in a quarter the subluxation recurred after 12 months, but with no difference to function. They felt this was more of a problem with the Hintegra prosthesis than with the Mobility. One factor in anterior subluxation is how much sagittal tilt is put on the tibial component; the standard aimed for is 4-6 degrees from perpendicular to the tibial axis, but it is hard to be this accurate, and the image intensifier can easily give a false impression.

Minor mal-rotation of the components should not matter in mobile bearing prostheses because the tibia is usually flat and unconstrained; but if excessive, it in some prostheses it causes impingement of the meniscus and implant failure.

Even when corrected, 25% of those with pre-operative coronal deformity will recur. The literature brands these failures but in clinical practice some do well despite apparent problems on radiographs. Paul Cooke's concept of "safe failure" is when the talar component progressively subsides (possibly through AVN) until the malleoli support the weight. This is seen not infrequently in TAR's over 10

years old. Some malleoli are seen to hypertrophy as a result of their new function. Many patients complain of impingement symptoms but many are painless, and if so, there is no reason to revise them.

## References

1. Doets HC, Brand R, Nelissen RG. Total ankle arthroplasty in inflammatory joint disease with use of two mobile-bearing designs. *J Bone Joint Surg Am.* 2006;88:1272-1284.
2. Haskell A, Mann RA. Ankle arthroplasty with preoperative coronal plane deformity: short-term results. *Clin Orthop Relat Res.* 2004;98:103.
3. Wood PL, Deakin S. Total ankle replacement. The results in 200 ankles. *J Bone Joint Surg Br.* 2003;85:334-341.
4. Cornelis Doets H, van der Plaats LW, Klein JP. Medial malleolar osteotomy for the correction of varus deformity during total ankle arthroplasty: results in 15 ankles. *Foot Ankle Int.* 2008;29:171-177.
5. Hintermann B, Valderrabano V, Dereymaeker G, Dick W. The HINTEGRA ankle: rationale and short-term results of 122 consecutive ankles. *Clin Orthop Relat Res.* 2004;57-68.
6. Hobson SA, Karantana A, Dhar S. Total ankle replacement in patients with significant pre-operative deformity of the hindfoot. *J Bone Joint Surg Br.* 2009;91:481-486.
7. Kim BS, Choi WJ, Kim YS, Lee JW. Total ankle replacement in moderate to severe varus deformity of the ankle. *J Bone Joint Surg Br.* 2009;91:1183-1190.
8. Ryssman D, Myerson MS. Surgical strategies: the management of varus ankle deformity with joint replacement. *Foot Ankle Int.* 2011;32:217-224.
9. Mann JA, Mann RA, Horton E. STAR ankle: long-term results. *Foot Ankle Int.* 2011;32:S473-S484.
10. Lee KT, Jegal H, Park YU et al. Comparison of sagittal subluxation in two different three-component total ankle replacement systems. *Foot Ankle Int.* 2013;34:1661-1668.

## Wound and Neurovascular Complications of TAR

National Joint Registries pick up some major complications like revision for infection, but are not designed to pick up minor wound complications or nerve injuries. We are left then with case series or meta-analyses based on case series – which are often reported by a single surgeon operator. Serious vascular complications are very rare and are not further considered.

Definitions of various wound complications can be problematic and are often not spelled out. Most would consider a deep infection to be one requiring further operative intervention. Other terms like superficial infection, delayed healing, minor central skin necrosis and dehiscence are used with the assumption that their meanings are universal.

Goldberg's team reviewed the literature on 7942 TAR's<sup>1</sup>. They found an overall rate of 2.4% for superficial infection; 1.1% for deep infection; 1.3% for major intra-operative nerve injuries.

Saltzman et al<sup>2</sup> studied 593 STAR ankles in a prospective multi-centre trial of TAR versus fusion, and documented post-operative status meticulously. They found a 22% rate of loss of sensation after TAR, most commonly around the medial side of the navicular, presumably from injury to the medial branch of the superficial peroneal nerve. Most surgeons will gloss over this and treat it almost as part of the procedure. They also reported a 4.5% superficial infection rate, major infection 1.2%, and major wound complications 2%, one of which required a revision.

Lee et al<sup>3</sup> couched their first 50 cases in terms of a learning curve by arbitrarily dividing them into the first 25 and second 25 cases. There was a 12% nerve injury rate in the first group, none in the second. One deep infection was treated by revision to fusion. There were three “minor wound complications” but here the problems with nomenclature are illustrated as some of these required split skin grafts, which most surgeons would regard as an appreciable complication.

Wood<sup>4</sup> had 2.5% minor wound problems, including one patient who was revised to a fusion as a result.

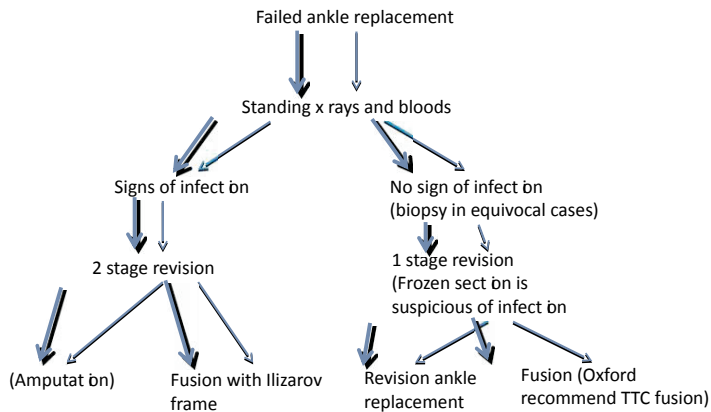
Treatment for superficial infection is generally regular dressing changes and oral antibiotics. Deep infections are most wisely managed according to the Oxford protocol<sup>5</sup> (see below) with a two stage procedure leading to fusion.

In order to reduce deep infections, IV antibiotics must be given. The low rate of infection makes it virtually impossible to properly test interventions designed to reduce it further. Clean air theatres with laminar flow are often used. Different methods of skin preparation have been studied in the foot and ankle<sup>6</sup>, with post-preparation bacterial culture number as the outcome measure. The best preparation was alcoholic chlorhexidine used twice, but it is unknown whether this translates into fewer clinical infections.

There may or may not be a benefit to the surgeons wearing a ventilated “space suit” that covers the head. The New Zealand joint registry appeared to show that laminar flow and “space suits”, both independently and together, were associated with increased revision for infection in THR and TKR<sup>7</sup>. The modern suit has no exhaust, unlike the Charnley system that historically was associated with a lower infection rate. Positive pressure at the head end of modern suits expels air from the lowest extremity, whereas the Charnley suit sucks air from the bottom to the top, and this may well affect the spread of microbes from the surgeon's body.

Surgical technique is of course relevant to wound complications. In the anterior approach the skin is thin and retraction must be careful, preferably avoiding self-retainers as they increase the tension on the skin.

## Protocol for managing failed TAR (Oxford group – JBJS Br 2006)



### Summary

- Superficial peroneal nerve injury is common but rarely significant.
- 2-5% of TARs develop a superficial infection which by definition will not have a significant effect on outcome if treated appropriately.
- Deep infection rate is just above 1% and is a serious complication often necessitating revision to fusion.

### References

1. Zaidi R, Cro S, Gurusamy K et al. The outcome of total ankle replacement: a systematic review and meta-analysis. *Bone Joint J.* 2013;95-B:1500-1507.
2. Saltzman CL, Mann RA, Ahrens JE et al. Prospective controlled trial of STAR total ankle replacement versus ankle fusion: initial results. *Foot Ankle Int.* 2009;30:579-596.
3. Lee KB, Cho SG, Hur CI, Yoon TR. Perioperative complications of HINTEGRA total ankle replacement: our initial 50 cases. *Foot Ankle Int.* 2008;29:978-984.

4. Wood PL, Prem H, Sutton C. Total ankle replacement: medium-term results in 200 Scandinavian total ankle replacements. *J Bone Joint Surg Br.* 2008;90:605-609.
5. Kotnis R, Pasapula C, Anwar F, Cooke PH, Sharp RJ. The management of failed ankle replacement. *J Bone Joint Surg Br.* 2006;88:1039-1047.
6. Yammine K, Harvey A. Efficacy of preparation solutions and cleansing techniques on contamination of the skin in foot and ankle surgery: A systematic review and meta-analysis. *Bone Joint J.* 2013;95-B:498-503.
7. Hooper GJ, Rothwell AG, Frampton C, Wyatt MC. Does the use of laminar flow and space suits reduce early deep infection after total hip and knee replacement?: the ten-year results of the New Zealand Joint Registry. *J Bone Joint Surg Br.* 2011;93:85-90.

### **TAR complications: Discussion**

It was felt by many that STARs caused more lateral fractures, the Mobility more medial. Most implants do well in the first 5-10 years but, as with hips, it may be later in their life that they start to be differentiated.

Mr Cooke clarified that “safe failure” or subsidence is safe only if the foot is square to the floor; as soon as there is tilt, the TAR fails catastrophically and clinically and requires revision.

There was a discussion about altering the approach to go lateral to EHL, more direct on to the talus and needing less retraction on the skin, but the consensus was clearly against this.

More than one surgeon uses prophylactic wire up one or both malleoli. This stops the saw going too far out and also makes ORIF easier if needed. In the USA several surgeons put a screw in the medial malleolus for every case!

Heterotopic ossification is another method by which a TAR may fail clinically, causing posterior impingement for instance. One way of dealing with it is to remove the insert, use rongeurs to get it out, and replace the liner; or use a posteromedial or posterolateral approach. Two surgeons had used a posterior incision to get at heterotopic bone.

Late malleolar fractures can almost be seen as a separate disease caused by malalignment. Osteoporosis and osteomalacia may also be factors.

## Malunion of Triple Arthrodesis

Open reduction and triple arthrodesis for the planovalgus foot is a technically difficult procedure. Because of this, malunion or mal-alignment is a well-recognised complication and can be seen in up to 15% of patients (1).

### **Current practice 2014:** Triple fusion for planovalgus foot

90% have had a suboptimal result in terms of alignment in their own practice

Indeed S. Haddad can be quoted as saying:

“The precarious balance required to create a plantigrade foot via triple arthrodesis with pre-existing deformity leaves even the most skilled surgeon challenged”

So if you experience malunion in such patients you are in good company. However is it something that we actively look for or consent patients for?

### **Current practice 2014:** Triple fusion for planovalgus foot

25% check and document malalignment at 3/12 post-op

60% consent patient for malalignment

Thus full appreciation of the plano-valgus deformity is vital to understand how to correct it fully during triple arthrodesis and prevent mal-alignment. Assessment of the patient pre-operatively requires full clinical examination and should include assessment of the mid/forefoot in relation to a corrected hindfoot.

Radiographs should include weight bearing views of both ankle and foot, cobey views and a CT. A weight bearing PED CT can be although of as the gold standard although this is not currently available in many centres.

The apex or CORA of a planovalgus deformity is at the subtalar joint and there is often additional forefoot supination. Both a calcaneal osteotomy and a lateral column lengthening address the deformity away from this point and therefore may cause translation and mal-alignment. This has led to the introduction of sinus tarsi correction of the planovalgus deformity, particularly in the adolescent (2,3). Deformity is best corrected at the CORA and thus each correction tailored to the individual deformity.

### **Current practice 2014:** Medial approach for severe flat foot

20% routinely use this approach

Medial approach should be used especially if tethered or poor lateral skin or a dislocated TN joint

### **Current practice 2014:** Gastrocnemius/ Achilles lengthening

20% always do this when doing a triple for a flat foot

60% do this according to findings on table

Patients should always be assessed for gastrocnemius/Achilles tightness and corrected when needed. This allows deformity correction.

**Current Practice 2014:** Lateral column lengthening as well as triple arthrodesis

10% of people routinely do this

**Current practice 2014:** Bone graft for triple arthrodesis

5% currently do this

### **Consensus**

We propose that there is individual assessment of the severe stiff flat foot deformity. All patients should be consented for malalignment and have their pre and post-operative alignment documented. A triple fusion should be combined with the procedures in an “a la carte” manner rather than a “carte blanche” to ensure full correction of the deformity at the CORA.

- Gastrocnemius/ Achilles lengthening to allow reduction
  - Tricortical or “sugarcube” graft in sinus tarsi
  - Lateral column lengthening
  - Fusion of 1<sup>st</sup> TMTJ
- 
1. *J Bone Joint Surg Am.* 1999 Oct;81(10):1391-402. [Saltzman CL](#)1, [Fehrle MJ](#), [Cooper RR](#)  
**15% residual deformity.** Triple arthrodesis: twenty-five and forty-four-year average follow-up of the same patients.
  2. Vedantam R, Capelli AM, Schoenecker PL: subtalar arthroereisis for the correction of planovalgus foot in children with neuromuscular disorders. *J Paed Orthop* 1998;18
  3. Giannini BS, Ceccarelli F, Surgical treatment of flexible flat foot in children, 4 year follow up study *JBJS Am* 2001: 83

## Calcaneal Fracture Malunion

### Current practice 2014: Calcaneal fractures

80% would operate on calcaneal fractures

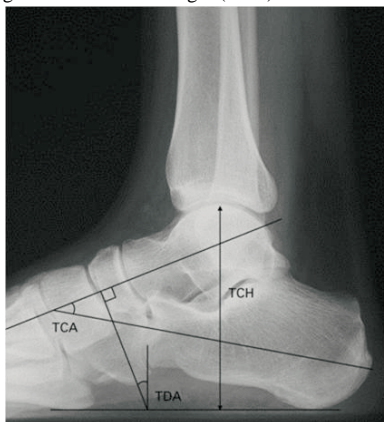
Of those who would operate 100% would fix a 2 part fracture

The indications to operate are to decrease the likelihood of poor outcome. However, which fractures do better and which do not benefit from surgical intervention is not fully understood and what is required is publication of recent research to highlight this.

The main aim in treating calcaneal fracture is to avoid malunion as its sequel such as:

- Subtalar arthritis
- Calcaneo-cuboid arthritis
- Sub-fibular impingement
- Peroneal tendon pathology
- Loss calcaneal height
- Hindfoot varus
- Widened heel
- Tibial/ sural nerve irritation

This will usually be identified from the clinical history and clinical examination focusing on pain, gait, heel alignment and motion of the ankle and subtalar joints. Radiographically these sequela can often be identified by measuring the talocalcaneal height (TCH) the Talocalcaneal angle (TCA) or the



Talar-declination angle (TDA).

In 1996 Stephen and Sanders (1) identified three subgroups of calcaneal malunion that were then modified by Rammelt and Zwipp (2) into six subgroups, in 2013. This latest classification can be used to direct future surgical intervention.

Type	Characteristics	Treatment options	Quality
0	Extra-articular or intra-articular malunion without arthrosis	Joint-preserving osteotomy	
I	Subtalar joint incongruity with arthrosis	Subtalar in situ fusion	A Solid malunion
II	Additional hindfoot varus/valgus	Subtalar bone-block fusion (+ osteotomy)	
III	Additional loss of height	Subtalar bone-block fusion (+ osteotomy)	B Nonunion
IV	Additional lateral translation of the tuberosity	Oblique calcaneal osteotomy with subtalar fusion	
V	Additional talar tilt at the ankle joint	Ankle revision, subtalar bone block fusion and osteotomy	C Necrosis

The aim of revision surgery is maintain or correct any mal-alignment in particular varus and restore the TCH, TCA and the TDA. This may require a bone block arthrodesis of the subtalar joint, particularly if there is >8mm of height loss.

**Current practice 2014:** Subtalar arthrodesis for calcaneal malunion.

80% use a bone block selectively to restore height

Coronal plane deformity should be addressed with a calcaenal osteotomy such as the closing wedge (Dwyer), the vertical slide (Huang) or through the primary fracture line (Romash). However these are rarely performed especially inconjunction with a subtalar fusion.

### Consensus

- Calcaneal malunion involves an incongruent subtalar joint, varus malalignment and tuberosity displacement.
- Degenerate joints and malalignment need to be addressed if revised

### References

1. Stephens HM, Sanders R. Foot Ankle Int. 1996 Jul;17(7):395-401.
2. Rammelt S, Zwipp H. Int Orthop. 2013 Sep;37(9):1707-17.

## Sequale of Talar Neck Fractures

In the management of acute talar neck fractures it is vital to “get it right first time” as the possible sequale include:

- Maliunion/ malalignment
- Avascular necrosis +/- collapse
- Ankle arthritis
- Subtalar arthritis

- Uncoupling of ankle, hindfoot and midfoot mechanics

To do this a CT scan in the acute setting enables the surgeon both to measure alignment displacement, to look for subluxation of ankle or subtalar joint and classify the Hawkins type. Hawkins divided talar neck fractures into 4 types :

- I. Undisplaced
- II. Subtalar dislocation
- III. Subtalar & Ankle dislocation
- IV. Subtalar, ankle and talonavicular dislocation

#### **Current practice 2014:** Talar neck fractures

90% would treat type I fracture conservatively

Type I fractures are essentially undisplaced and can therefore be treated conservatively. All other fractures are best treated surgically. This is best performed by either a double approach or the dorsomedial approach alone. Timing of surgery doesn't have a clear effect however prompt intervention is usually advocated due to the risks of AVN especially with higher grade injuries. Type III and IV injuries should be treated as an emergency to convert them to a type II and temporary stabilisation with external fixation

#### **Current practice 2014:** Post operative treatment talar neck fractures

40% would NWB for 6/52

50% would NWB for 12/52

### **Malunion**

#### **Current practice 2014:** Talar malunions

35% present had dealt with a malunion within the past year

Malunion deformity tends to be medial shortening, varus and extension.

This is addressed through the dorsomedial incision at the main area of comminution in the dorsomedial cortex. Restoration of length to prevent varus is paramount. In the acute phase this is achieved with a medial plate and/or screws however in the presence of an established malunion then a medial osteotomy to correct length, varus and extension with interposition tricortical grafting should be performed in addition. When there is an established malunion then the presence of concomitant arthritis in either the ankle and/or subtalar then salvage treatment with fusion procedures should be considered.

## **Avascular necrosis**

Avascular necrosis (AVN) is a pathological process characterised by:

- Loss of blood supply
- Cellular death
- Collapse of bony structure
- Joint derangement

In Hawkins' classification we are reminded of the somewhat precarious blood supply of the talus. Disruption in blood supply can occur from traumatic injury and render the talus avascular; the risk of which increases as displacement increases. However there are other causes that should be considered particularly in the absence of a history of significant trauma.

AVN can be detected on plain radiograph or on MRI when subtle and staged according to the Ficat staging. T2 weighted images allow differentiation between necrotic and hyperaemic areas, highlighting that AVN doesn't have to involve the whole bone perhaps allowing targeted therapy.

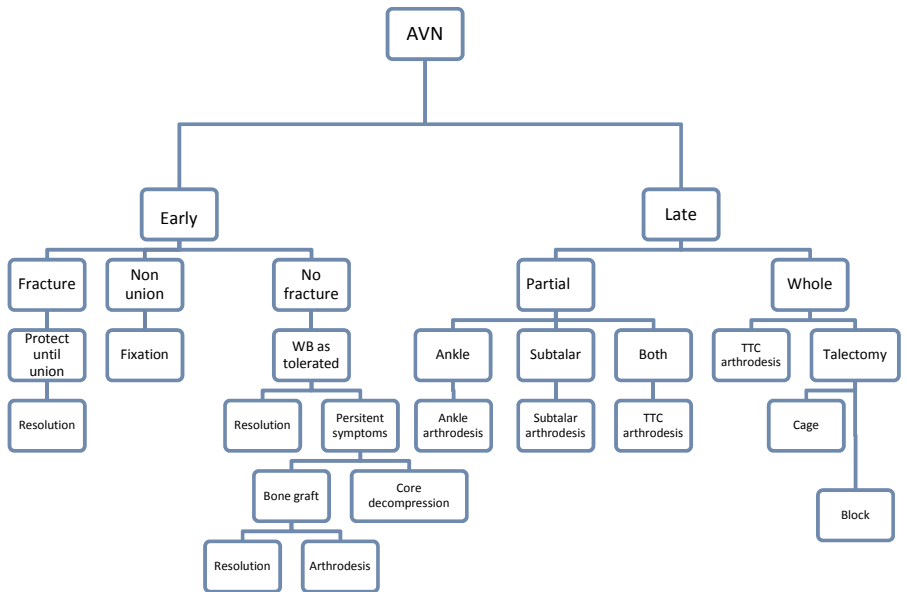
In 2004 Horst et al (1) suggested the way of addressing AVN of the talus illustrated in the figure 1. Patients with early AVN need to undergo joint preserving surgery. This consists of decompression, grafting or re-fixation of a non-union. Treatment of late AVN depends on the proportion of the bone/joint involved but usually requires joint fusion or excision of the talus and bone grafting to restore height. Any such surgery is a big undertaking and requires long, slow rehabilitation with 3/12 in a plaster (6/52 NWB) and 3/12 in a protective boot.

## **References**

1. Horst et al Foot Ankle Clin N Am 9 (2004) 757–773

## **Consensus**

- All but type I fractures should undergo ORIF
- Type III & IV should undergo emergency surgery to convert to type II and then wait definitive surgery as the soft tissues allow
- Medial length, varus and extension deformity are what we are trying to avoid
- Patients should be NWB for 6 weeks and protected for 3/12
- AVN should be addressed as suggested by Horst



## Navicular Stress Fractures

Navicular fractures are rare in isolation. Acute fractures are either avulsion of the tuberosity or a body fracture. Stress fractures of the navicular occur due to repetitive stress in a region of poor blood supply. They originate at the proximal dorsal articular surface and propagate distally and perpendicular to the longitudinal axis in central third. They usually present insidiously and plain radiographs are often normal. An MRI scan can be difficult to differentiate between a stress reaction and a fracture, whilst a bone scan is sensitive but non-specific. The most widely used classification system depends on CT findings (1):

- I. Dorsal cortical break
- II. Involves fracture propagation into body
- III. Complete fracture exists plantar aspect

**Current Practice 2014:** Treatment of un-displaced Type III navicular fracture

65% would treat surgically

35% would treat conservatively

All would keep them NWB for 6-8/ 52

**Current practice 2014:** Type III navicular fracture no sclerosis

90% would operate percutaneously

10% would perform ORIF

The primary reason for non-union is the weight bearing status, with those treated WB 3 times as likely to get a non-union as those treated NWB (2,3). A systematic review in 2010 concluded that fracture type did not correlate with outcome, regardless of treatment. The literature is supportive of the conservative management of undisplaced fractures as long as they are kept NWB for 6-8/ 52.

The indications to operate are displacement, failure of conservative management or delayed presentation and sclerotic fracture margins. This is usually performed percutaneously for acute fractures and open for sclerotic fractures or non-unions, although a sclerotic fracture can be freshened up percutaneously with a k wire to avoid opening the fracture. After reduction of the fracture with debridement of the fracture margins as required, compression screws should be placed from lateral to medial. Bone grafting and locking plates can be reserved for the rare case of non-union after ORIF, which occurs in <5% of cases (4). Such cases also require that any co-existing foot deformity is taken into consideration.

## Consensus

- Type III fractures should undergo surgical fixation
- Patients should be kept NWB for 6 weeks
- ORIF if there are sclerotic edges

## References

1. Saxena A, Fullem B, Hannaford D. Results of treatment of 22 navicular stress fractures and a new proposed radiographic classification system. *J Foot Ankle Surg.* Mar-Apr 2000;39(2):96-103.
2. Stress fractures of the tarsal navicular: a retrospective review of 21 cases. *JBJS* 1982;64A:700-12
3. Outcome of conservative and surgical management of navicular stress fractures in athletes. *Am J Sports Med* 1992;20:657-66
4. Torg et al. Management of tarsal navicular stress fractures: conservative versus surgical treatment: a meta-analysis. *Am J Sports Med* 2010; 38:1048-53
5. Fitch KD, Blackwell JB, Gilmour WN. Operation for non-union for stress fracture of the tarsal navicular. *J Bone Joint Surg Br* 1989;71:105–10.

**Convened participants of the 2014 Round Table Meeting were:**

Amit Amin  
Tom Ball  
Stephen Bendall  
Rick Brown  
Callum Clark  
Tim Clough  
Chris Coetzee  
Paul Cooke  
Nick Cullen  
Mark Davies  
Sunil Dhar  
Nick Geary  
Andy Goldberg  
Kurt Haendlmayer  
Matthew Henderson  
Mark Herron  
Mike Karski  
Senthil Kumar  
Andy Molloy  
Steve Parsons  
Anand Pillai  
Simon Platt  
James Ritchie  
Fred Robinson  
Ben Rudge  
Robert Sharp  
Ian Sharpe  
Dishan Singh  
Sam Singh  
Michael Stephens  
Nick Talbot  
Hiro Tanaka  
Rhys Thomas  
Ioan Tudur Jones  
Philip Vaughan  
Tim Williams  
David Williamson

# OrthoSolutions

Group



Ortho Solutions UK Ltd - UK  
West Station Business Park,  
Spital Road, Essex. CM9 6FF

Tel: +44 (0)1621 843 599  
Fax: +44 (0)1621 858 953  
Email: [sales@orthosol.com](mailto:sales@orthosol.com)

Ortho Solutions Inc - USA  
10901 W Toller Dr, Suite 205,  
Littleton, CO 80127

Tel: +1 (303) 495-5407  
Fax: +1 (303) 495-5408  
Email: [us.sales@orthosol.com](mailto:us.sales@orthosol.com)

Ortho Solutions Pty  
Au PO Box 1330,  
Milton, QLD. 4064

Tel: +61 (0) 4088468  
Email: [salespty@orthosol.com](mailto:salespty@orthosol.com)

**[orthosol.com](http://orthosol.com)**

© 2018 Ortho Solutions UK Ltd, the OS logo and the  
OxBridge logo are trademarks of Ortho Solutions UK Ltd.