

# Consensus Of The Round Table

## Padova 2011

*Mr. Timothy HD Williams MBBS FRCSG(Tr&Orth)*

*Mr. Dishan Singh FRCS(Orth)*



*Aspects of Orthopaedic Foot & Ankle Surgery*



## Preface

Most foot and ankle meetings currently adopt a format of a faculty lecturing to delegates with limited time for discussion. When I was approached by Ortho Solutions to help organise a meeting, I felt that a Round Table format where all attendees would review the literature and present their individual experience on a topic with ample time for an informal discussion of the subject could be more conducive to an effective learning experience. My suggestion was well received by my co-course organisers and the company.

We selected 3 controversial topics for discussion and assembled in Padua for our meeting. There was considerable debate but we were able to reach a consensus on many issues. Tim Williams kept a record of the discussions and this booklet collates the literature review and the views of all those who participated. We hope that you will find the consensus views helpful: for example, it was of value to know that the participants have had no complications in performing a calcaneal displacement osteotomy from either the direct approach or the extended lateral approach to the os calcis .

This booklet does not represent Level I evidence derived from prospective randomized controlled trials but represents the compilation of anecdotal reports and small case studies based on the combined experience of 30 delegates. I hope that you will find something of use and relevant to your own practice.

Dishan Singh, MBChB, FRCS, FRCS (Orth)

Consultant Orthopaedic Surgeon



# Consensus Of The Round Table

## Padova 2011

*Mr. Timothy HD Williams MBBS FRCSG(Tr&Orth)*

*Mr. Dishan Singh FRCS(Orth)*



### Aspects of Orthopaedic Foot & Ankle Surgery

1. Morton's Neuroma
2. Management of Stage II *tibialis posterior* insufficiency
3. Lesser toe *metatarsophalangeal* Joint instability

Convenors:

Mr. D. Singh,

Mr. P. Cooke,

Mr. N. Geary,

Mr. A. Robinson

Hosts: Ortho Solutions

Distilled in this document are the thoughts and opinions with consensus where possible of 30 Orthopaedic Foot and Ankle Consultant Surgeons who gathered from across Italy, France, Israel and the United Kingdom. Though eminence rather than true evidenced based medicine this represents the concepts of over 200 years of combined experience. A basis of invited lectures introduced open and frank discussion from which consensus was sought. The statements herein only represent those of individuals and no claim is made that they are irrefutable. All The percentage figures quoted represent the proportion of the surgeons present who voted on the subject in discussion.



## Chapter 1

### **Morton's Neuroma**

A misnomer in too many ways, a Morton's Neuroma was neither originally described by Morton nor represents a true neuroma. Recognising the contribution of T.G Morton(1) would better be to describe the 3rd and 4th metatarsalgia associated with the condition (as his description was clinical, suggesting the concept of a neural pathoanatomy); he however advocated excision of the fourth metatarso-phalangeal joint as the cure.

Dr Carlo Biz of Padua University presented photographs of the original anatomical illustration with description of a neuroma on the 3rd common digital nerve (CDN) associated with a Hallux Valgus in an anatomical letter dated 1835 by Filippo Civinini of Pisa, Italy. Clinical correlation with this pathology is later attributed to Lewis Durlacher in 1845(2). Father(TG) and son(TSK) Morton were accredited with the eponymous syndrome from articles dating 1876 and 1893.

A.E. Hoadley(3) of Chicago contributed with the first case report which married the clinical pathology with successful surgical excision of the nerve.

It may now be too late and in fact wrong to change the eponym, particularly in the face of the perceived understanding of many associated specialities. Indeed we continue to use the term in this document but give due historical respect to the contributors and their role.

## The Pathology

Controversy remains about the exact nature of the condition. Modern imaging techniques raised the discussion of the role of the intermetatarsal (IM) bursa. It was agreed that whilst normally lying above the IM ligament when inflamed or enlarged a bursa can (by USS) be seen to extend distally beyond and below the ligament and hence around a digital nerve. The irritative effect of this was surmised to cause the symptomatic neuritic symptoms. This had been seen at surgical exploration by some surgeons present.

Anecdotal surgical experiences discussed agreed that the gross appearance of the nerve may occasionally be normal, with little or no localised mass. Also noted was a tendency for the CDN to be kinked around the distal edge of the deep transverse metatarsal ligament. Subsequent resolution of the symptoms with excision supported the concept of an irritative neuritis as a recognisable stage in the pathology.

In support of this it was commented that a study(4) had reported the asymptomatic presence of a neuroma in up to 30% of a normal population when studied with MRI.

Despite being a common foot problem the true pathology remains a multifactorial anathema for further discussion.



## Diagnosis

### History, Examination & Special Investigations.

Central ray metatarsalgia radiating centrifugally of ache and burning in nature are associated with the neuritic symptoms in a specific webspace distribution.

Consideration of 1st-2nd (and to a lesser extent 2nd – 3rdweb space) Morton's Neuroma must be circumspect as these are rare and often a different pathology is present. Focussed assessment for 2nd metatarso-phalangeal joint synovitis will often reveal this more common diagnosis.

Mulder's click is a dynamic test that can support the diagnosis by reproducing symptoms in the affected webspace. The presence of just the palpable or even audible click alone was questioned as a diagnostic criterion, being witnessed to be present even in asymptomatic populations.

A dynamic stretch test originally described by Greiss(5) is being given increasing credit based on its anatomical principles.

Adjunctive supporting evidence is provided by imaging modalities including MRI and USS.

It was felt that though operator dependant, USS enables a dynamic assessment of Morton's with the performing of a Mulder's click whilst visualising the lesion.

Concomitant USS guided injection can be both diagnostic as well as symptom relieving. Further more, it can help differentiate between a true Morton's and a contributing bursa. With a Morton's the fluid will track around the lesion, whilst with bursae it is seen to track along the nerve and fill like a balloon. The surgical implication of this as previously discussed remains of controversy.

A caveat was highlighted:

in the presence of a particularly large mass (seen on USS) an MRI should be sought as Sarcoma's can present with similar symptoms

## Conservative Treatment Options

Initial management including activity modification, footwear adjustments and insoles with a metatarsal dome were advocated by all in appropriate patients.

There was **consensus** (96%) on the use of a targeted corticosteroid injection.

- There was division on the need for USS guidance (35%) versus a blind outpatient technique (65%) for these injections, both sides reporting similar satisfaction.
- Surgeons were again divided on the number of injections sensible and the time lag between them.
  - There was **consensus** though on using **no more than 4** injections in close succession.
- There was **consensus** (80%) on the use of depo-medrone (40mg in 1ml).
- There was **consensus** on **not** using triamcinolone.
- There was **consensus** (96%) on **not** using sclerosants (alcohol/phenol).
- There seemed to be inconsistency in the types and concentrations of sclerosants used when the literature had been read by those present. The principle in the studies was one of injection into the nerve and so all articles which advocate unguided injections of sclerosant, should be viewed with some scepticism.
- Concern was raised following a number of anecdotal reports of chronic pain following alcohol injections and these are to be collated for future presentation.

More experimental modalities including cryotherapy, shockwave and radiofrequency ablation were recognised but not undertaken or advocated by any members at present. Results of proper controlled trials should be awaited

## Surgical Management

There was **consensus** that there is reduced demand for surgical excision with 70% now performing less than 15 cases a year.

There was **consensus** (90%) on a dorsal web space versus plantar surgical approach in primary resections.

There was equality of opinion (**50%/50%**) between a plantar and repeat dorsal incision for revision surgery.

There was **consensus**(100%) on the surgical excision of the Morton's to include at least 3cm of nerve proximally and normal nerve beyond the bifurcation distally.

There was consensus on the sharp nerve division proximally to encourage stump retraction within the intrinsic muscle belly.

- A significant minority (30%) additionally cauterise the nerve with bipolar diathermy prior to division.

There was **consensus**(100%) on the use of a tourniquet for the procedure.

- There was equality of opinion (50%/50%) between those who routinely deflated the tourniquet prior to closure and those that did not.

There was **consensus**(100%) to allow patients to fully weight bear immediately in the post-operative period.

The technique of isolated intermetatarsal ligament release as a primary procedure was discussed.

- It was advocated in situations where the nerve is grossly normal in appearance or seen to kink around the ligament hence 'decompressing' the nerve could remove the causative factor.
- In situations where exploration found the Morton's lesion to be entirely distal to the intermetatarsal ligament a suggestion was made that the ligament should not be divided.

Anecdotal cases were presented of splaying of the metatarsals following a dorsal approach for primary Morton's excision which were later resolved by surgical reconstruction of the ligament with a number of different techniques.

The surgical management of (albeit rare) adjacent web space primary Morton's neuromata produced disparate opinion.

- 20% carefully excising both at the same surgery.
- 35% excising the more symptomatic webspace and decompressing the adjacent with IM ligament division.
- 45% advocated excising the more symptomatic lesion and leaving the less so completely for a second surgery as necessary.

An open anecdotal discussion on the cause and management of recurrent or persistent symptoms suggested a number of potential causative factors.

- A second nerve remaining in the webspace, found at revision excision which may represent:
  - An early division of the common digital N' not recognised.
  - An anomalous duplicated Nerve derived from a neighbouring CDN.
- Normal variant adhesions of the common digital nerve along its length may prevent stump retraction into the muscle belly thus remaining subject to intermetatarsal irritation.
- The formation of a true stump neuroma.

Re-dissection and division more proximally or excision of any extra neural tissue was advocated and a single successful case of burying the stump in a metatarsal drill hole was applauded.

## References

Morton TG: A peculiar and painful affection of fourth metatarsophalangeal articulation. Am J Med Sci 71:37-5

Durlacher L: A Treatise on Corns, Bunions, the disease of nails and the general management of feet. London, Simpkin, Marshall, 1845

Hoadley ARE: Six causes of metatarsalgia. Chicago Med Rec 5:32-37, 1893

Bencardino J, Rosenberg ZS, Beltran J, et al: Morton's Neuroma: is it always symptomatic? AJR Am J Roentgenol. 2000 Sep;175(3):649-53

DJ. Cloke; ME. Greiss: The digital nerve stretch test: A sensitive indicator of Morton's Neuroma and neuritis. Foot and Ankle Surgery, Vol. 12, Issue 4, 2006, p201-203

## Chapter 2

### Treatment of 2<sup>nd</sup> Stage Tibialis Posterior Tendon Dysfunction

Tibialis posterior (tib. post.) dysfunction remains a mystery in its primary cause. We resort to the term multifactorial as it is a recognised condition with multiple associations. We therefore consider it as a continuum of pathology synonymous with the clinically observed acquired adult planovalgus foot, gathering features as the condition progresses.

#### Classification

There was **consensus** (100%) that the Myerson modification<sup>(1)</sup> of Johnson and Strom's classification<sup>(2)</sup> including his later sub-classification of 2<sup>nd</sup> stage is a succinct and usable system in everyday clinical decision making.

##### **Stage 1** (*swelling and pain along course of tendon, intact power and no deformity*)

There was a majority (66%) that felt the symptoms of stage 1 dysfunction should be re-considered as a *de-novo* entity as the pathology was felt to be less early tendonosis but one of a true tendonitis or paratendonitis. This then being a pre-emptive pathology which on some occasions may contribute to tib. post. dysfunction.

The judicious use of corticosteroid injection in stage 1 was of contention.

- 50% using the technique in situations of a confirmed tenosynovitis (with **no** tendonitis/tendonosis), splinted subsequently for varying amounts of time (the majority of these using an USS guided technique).
- A smaller group (23%) refused to inject around this tendon for fear of rupture.
- Two (8%) surgeons advocated an autologous blood injection in to the sheath.

##### **Stage 2** (*Mainly medial symptoms with mild medial arch collapse. Single stance heel raise still possible; the deformity is correctable*)

Discussed was the Truro sub-classification of Parsons<sup>(3)</sup> from 1997 which is based on forefoot supination once the hindfoot is held corrected during clinical examination. (See Table).

Truro (3)sub classification of Stage 2 tib. Post. dysfunction	
2a	Flatfoot deformity which has progressed but is fully passively correctible
2b	Flatfoot deformity which has progressed but is fully passively correctible and in which forefoot varus is greater than 15deg.
2c	Flatfoot deformity which has progressed; the hindfoot is fully passively correctible but the forefoot is not.

There was **consensus** (74%) that the assessment for surgery of a patient with 2<sup>nd</sup> stage tib. post. should include an MRI scan in order to uncover any medial column, arthritic change. This could / would alter management potentially from a joint preserving to a joint sacrificing procedure which many felt was under-called with just radiographic assessment.

There was **consensus** that caught early, conservative measures including orthoses, anti-inflammatories and physiotherapy were appropriate.

## Surgical Techniques for 2<sup>nd</sup> stage tibialis posterior dysfunction

### Laterally Based Hindfoot surgery

There was **consensus** (100%) that a medial displacement calcaneal osteotomy provides a reproducible hindfoot correction.

A significant minority (33%) consider the use of Lateral Column Lengthening in select, more severe cases.

There was **consensus** (96%) that Arthroereisis would not routinely be performed.

### 1. Medial Displacement Calcaneal Osteotomy

This was the preferred hindfoot correction technique in all cases by 2/3rds (66%) of the table.

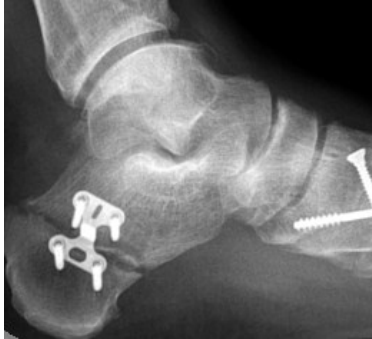There was **consensus** (100%) on the need for a calcaneal osteotomy in all cases with a valgus heel.

There was **consensus** (100%) that a calcaneal osteotomy alone was insufficient to provide a long lasting clinical outcome.

There was equality in the surgical lateral approach to the osteotomy:

- 50% through a direct oblique incision parallel to the planned saw cut.
- 50% through the extensile approach of Atkin.

The historically established method of osteotomy fixation with compression screw was recognised though a 'Step' locking plate concept was promoted. Anecdotal experience reported a larger and more controlled heel shift.



Calcaneal Step Plate (Ortho Solutions)

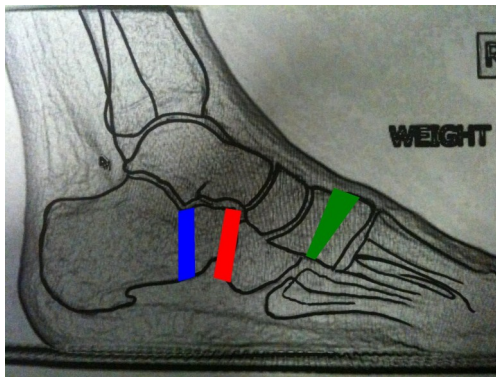
## 2. Lateral Column Lengthening




33% undertook this procedure on occasion in clinical practice. Suggested and agreed valuable indications for the procedure included:

- Extreme mid-forefoot abduction as seen with almost complete uncovering of the navicular in the AP foot x-ray.
- Talonavicular joint(TNJ) subluxation seen on a weightbearing lateral x-ray.
- A clinical finding of spontaneous planus correction only at the terminal end point of tiptoe/equinus stance test.
- Arthritic change in the calcaneo-cuboid joint

There was consensus (80%) among its users for surgical technique<sup>(4)</sup>.

- 80% Extra-articular distract on calcaneal osteotomy (**Evans**)
- 20% Distract on calcaneo-cuboid joint (**CCJ**) arthrodesis



-  Evans Osteotomy
-  CCJ distraction arthrodesis
-  Cotton Osteotomy

Though witnessed to be effective in deformity correction concerns were raised:

- High rates of non-union.
  - Some of which it was felt is being improved with the newer locking 'H' plate technology.
- Soft tissue complications including sural neurapraxia and wound breakdown.
- Subtalar and Talonavicular joint stiffness and latterly arthrosis.

## Medially Based mid/forefoot surgery

There was **consensus** (100%) that in the absence of medial column arthrosis an extra-anatomical tendon transfer was the appropriate primary procedure.

There was division over the primary technique of choice:

- 80% flexor digitorum tendon transfer
- 20% split tibialis anterior tendon transfer (Cobb)

There was **consensus** (100%) that the diseased portion of the tib. post. tendon should be excised in severe tendonosis.

There was **equality** (50%/50%) regarding the same decision in more moderate tendonosis.

There was **consensus** (100%) that the spring ligament and associated TNJ capsule requires attention in **all** cases.



There was **consensus** (100%) that the FDL should be harvested in preference to flexor hallucis longus (FHL).

A concept acknowledged by the table:

- Prior to FDL harvest the knot of Henry should be assessed for anatomic FDL-FHL adhesions using a tenodesis test.
  - Tugging on the FHL tendon proximally causes flexion of lesser toes as well as the hallux. If this not present then surgical tenodesis should be performed. If present it can be safely left.

More novel techniques acknowledged:

- Hamstring **autograft** reconstruction (open/arthroscopic).
- Hamstring **allograft** reconstruction (open/arthroscopic).
- Proximal FDL weave into tibial posterior healthy tendon along with distal transfer.

There was **consensus** that in the presence of medial column arthrosis joint sacrificing surgery becomes indicated.

- A pragmatic approach was advocated for the choice of joint to be fused based on the location of the maximal angular deformity associated with the arthrosis.

A significant minority (47%) utilise a plantarflexing 1<sup>st</sup> metatarsal osteotomy in situations of significant or passively un-correctable forefoot supination once the hindfoot surgery had been completed.

A second suggestion considered was the Cotton<sup>(5)</sup> osteotomy of the medial cuneiform. [See Previous Diagram]

## References

1. Myerson, M. S.: **Adult acquired flatfoot deformity. Treatment of dysfunction of the posterior tibial tendon.** J. Bone Joint Surg., 78A:780-792, 1996.
2. Johnson KA, Strom DE. **Tibialis posterior tendon dysfunction.** Clin Orthop. 1989; 239:196-206.
3. Parsons S, Naim S, Richards PJ, McBride D. **Correction and prevention of deformity in type II tibialis posterior dysfunction.** Clin Orthop Relat Res 2010 Apr;468(4):1025-32
4. Haeseker GA, Mureau MA, Faber F. **Lat. column lengthening for acquired adult flatfoot deformity caused by posterior tibial tendon dysfunction stage II: a retrospective comparison of calcaneus osteotomy with calcaneo-cuboid distraction arthrodesis.** J Foot Ankle Surg, 49: 380-4, 2010
5. Cotton FJ. **Foot statics and surgery.** N Engl J Med 214:353–362, 1936



## Chapter 3

### Instability of the 2nd Metatarsophalangeal Joint (MTPJ)

Lesser ray MTPJ instability is a common and an often frustrating problem to treat. Though occasionally seen in isolation it is usually found in combination with other pathologies including:

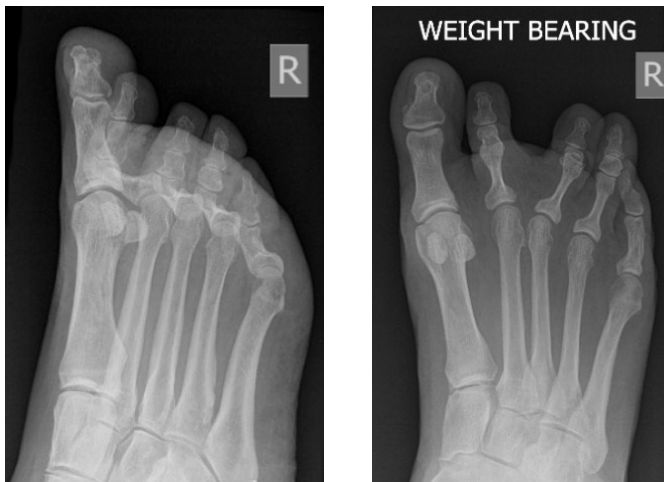- 1st ray defunctioning conditions such as hallux valgus
- Inflammatory polyarthropathies such as rheumatoid arthritis.
- Neuromuscular disorders including Charcot-Marie-Tooth.

The 2nd MTPJ is the most commonly affected presenting with metatarsalgia, a plantar keratosis, associated PIPJ flexion contracture and less frequently a sagittal plane deformity. A commonly encountered scenario is of the long 2nd metatarsal or so called Greek type foot.

We recognised two subgroups of instability:

1. Coronal plane deformity – Dorsal Instability.
2. Sagittal plane deformity – Lateral instability.

As so often in medicine, each is rarely seen in isolation and often coexists with final management strategies reflecting this.



Dorsal and Lateral Instability in the same patient

## Coronal Instability

Focussed assessment of 2nd MTPJ remains an important part of clinical examination. All too often a 1st/2nd or 2nd/3rd webspace Morton's neuroma is investigated and occasionally explored when this pathology is highly unusual.

There was **consensus** that a Lachman type assessment of the 2nd , and for that matter any lesser MTPJ will help clinically differentiate instability or synovitic irritation from webspace based pathologies.

Once established the assessment then concentrates on the reducibility of any deformity and flexibility of associated interphalangeal joint contracture.

Presented and used by most was the Blackburn(1) classification of clinical instability which provides a safe basis for management planning. (See Table)

	MTPJ	PIPJ
<b>Type 1.</b>	Reducible hyperextension	Reducible flexion
<b>Type 2.</b>	Reducible hyperextension	Fixed flexion
<b>Type 3.</b>	Fixed hyperextension or	Fixed flexion

Dhukaran et al 2002<sup>(1)</sup>

## Non-Operative Management

There was consensus that a trial of conservative management for all types of instability was valuable and occasionally curative, at least sufficient to manage symptoms.

Techniques volunteered included:

- Taping plantarwards of the proximal phalanx to reduce the MTPJ would often correct a flexible PIPJ through the action of the intrinsic muscle insertion.
- A Corticosteroid injection into the joint and tape afterwards.
  - Caution was advised to consent any patient of a small chance of exacerbating or causing clawing.
- Metatarsal dome type insoles in association with a deep toebox shoe.

## Surgical Management

Based on the Blackburn classification a variety of options were discussed

### Type 1. Instability (MTPJ reducible, PIPJ reducible)

Two common techniques were discussed.

- **A long flexor tenotomy:**– To correct both PIPJ & MTPJ deformities.

There was NOT consensus on the method. Surgical techniques included:

- Percutaneously at level just proximal to MTPJ with toe and ankle held in maximal dorsiflexion using a ‘Beaver’ blade
- Open at the level of the proximal phalanx through a plantar longitudinal or horizontal incision
- Open plantar approach at the insertion in to the distal phalanx
- **Flexor to Extensor Tendon Transfer (FETT):**– A minority commonly used this technique. Surgical variations included.
  - Through bone (Prox. Phalanx) delivery of the flexor tendon
  - All dorsal approach

### Type 2. Instability (MTPJ reducible, PIPJ fixed)

There was **consensus** that at least one to the PIPJ and MTPJ is required:

- PIPJ Surgery.
  - Majority (64%) perform a fusion with K-wire or more novel implants
  - A significant minority (36%) use an excision arthroplasty technique with or without K-wire stabilisation.
- MTPJ surgery
  - There was **consensus** (100%) that a progressive soft tissue release provides an acceptable correction. Surgical stages included:
    - I. ‘Z’ lengthening of EDL tendon with EDB tenotomy
    - II. Dorsal MTPJ capsular release
    - III. Medial and lateral capsule / collateral ligament release

- A minority (17%) occasionally undertook a Plantar Plate repair and approaches included:
  - Plantar approach and direct repair
  - Dorsal 'through joint' approach
  - Dorsal approach with metatarsal Weil's Osteotomy to open the joint and improve visualisation of the plate. Repair being a horizontal mattress suture of plantar plate through drill holes in the proximal phalanx. The Weil's then secured back in its anatomic location or shortened as required. This was originally described by L. Weil Jr(3)

### **Type 3. Instability.**

There was consensus that attention to the PIPJ and MTPJ is required:

- PIPJ Surgery
  - Majority (64%) perform a fusion with K-wire or more novel implants
  - A significant minority (36%) use an excision arthroplasty technique with or without K-wire stabilisation
- MTPJ Surgery
  - The majority preference was for a Weil's Osteotomy to decompress the joint and allow reduction. There was **consensus** that isolated 2nd MTPJ Weil's is appropriate though one must respect Maestro's parabola when indicated by a significant shortening
  - A Stainsby procedure was the routine procedure for just 3% (1 person) of those present though 27% use this option on occasions

There was **consensus** that isolated Metatarsal head excision or isolated hemiphalangectomy was **NOT** a recommended technique. An exception being in situations of multi-ray destructive arthropathy and a forefoot reconstruction.

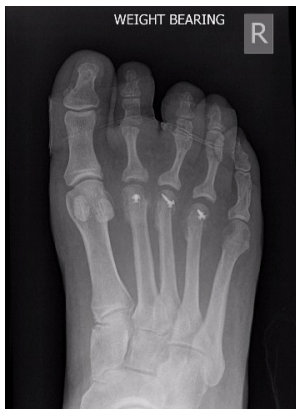## Sagittal Instability

Of en seen in conjunct on with some dorsal instability this remains a more frustrat ng surgical pathology. There was **NOT** consensus on any single surgical technique for stabilising lateral instability although a number of techniques were discussed.

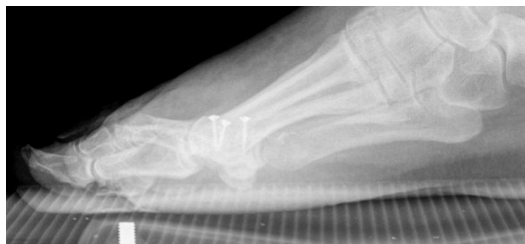It was agreed that the pathology seen during dissection was one of an attenuated collateral ligament in the convexity of the deformity with an intact ligament within the concavity. Subluxation of the extensor tendons into the concavity side of the lesion further exacerbates the problem.

Lateral instability surgical options discussed:-

- EDB to EDL tendon transfer
- Base of proximal phalanx closing wedge osteotomy
- Metatarsal neck closing wedge osteotomy
- FETT with flexor tendon drawn around the concavity of the deformity (counter-intuitively!)
- Weil's osteotomy with lateral translation into the concavity of the deformity with severance of normal collateral to tension the convexity side attenuated ligament(3)



Dorsal and Lateral instability treated with Weil's Osteotomies



## References

1. Dhukaram V, Hossain S, Sampath J, Barrie JL: **Correction of hammer toe with an extended release of the metatarsophalangeal joint.** JBJS [Br] 2002;84-B:986-90
2. Weil L(Jr), Sung W, Weil LS, Glover J: **Corrections of second MTPJ instability using a Weil osteotomy and dorsal approach plantar plate repair: A new technique.** Techniques in Foot & Ankle Surgery, March 2011
3. Bevernage BD, Deleu P-A, Leemrijse T: **The translating Weil osteotomy in the treatment of an overriding second toe: A report of 25 cases.** Foot and Ankle Surgery Vol 16, Issue 4, P153-158, Dec 2010



Convened participants of the 2011 Round Table Meeting  
were:

Patricia Allen  
Carlo Biz  
Chris Blundell  
Rick Brown  
Mike Butler  
Callum Clark  
Robert Clayton  
Simon Clint  
Gary Colleary  
Paul Cooke  
Mark Davies  
Sunil Dhar  
Israel Dudkiewicz  
Nick Geary  
Andrew Goldberg  
Simon Henderson  
Mark Herron  
Patrick Loxdale  
Rohit Madhav  
John McKinley  
James Ritchie  
Fred Robinson  
Robert Sharp  
Dishan Singh  
Sam Singh  
Tim Williams  
David Williamson

## Notes



# OrthoSolutions

Group



Ortho Solutions UK Ltd - UK  
West Station Business Park,  
Spital Road, Essex. CM9 6FF

Tel: +44 (0)1621 843 599  
Fax: +44 (0)1621 858 953  
Email: [sales@orthosol.com](mailto:sales@orthosol.com)

Ortho Solutions Inc - USA  
10901 W Toller Dr, Suite 205,  
Littleton, CO 80127

Tel: +1 (303) 495-5407  
Fax: +1 (303) 495-5408  
Email: [us.sales@orthosol.com](mailto:us.sales@orthosol.com)

Ortho Solutions Pty  
Au PO Box 1330,  
Milton, QLD. 4064

Tel: +61 (0) 4088468  
Email: [salespty@orthosol.com](mailto:salespty@orthosol.com)

**[orthosol.com](http://orthosol.com)**

© 2018 Ortho Solutions UK Ltd, the OS logo and the  
OxBridge logo are trademarks of Ortho Solutions UK Ltd.